

Case Report

Perforation of the Cervix by the Strings of An Intrauterine Device (IUD): A Novel Case Report and Systematic Review of the Literature

Panagiotis Peitsidis ^{1,2}, Chryssa Ekizoglou ³ Demetrios Spiliopoulos ¹, Stefanos Zervoudis ^{1,2} and Panagiotis Tsikouras ⁴

1.Department of Obstetrics and Gynecology Rea Maternity Hospital. Athens Greece

2.University of West Attica. Athens Greece

3. Institute of Child Health. Athens Greece

4. Department of Obstetrics and Gynecology Democritus University. Alexandroupolis Greece

Corresponding author: e-mail:peitsidiobgyn@gmail.com

Abstract: Purpose: Since their introduction, intrauterine devices (IUDs) have been associated with various complications. A very rare complication is the perforation of the cervix by the strings of the IUD. Purpose of the current study is to present a novel case of cervical perforation by the strings of a copper IUD and to perform a systematic review of the literature. Materials and Methods: The patient a 43-year-old attended the gynecology clinic in order to remove her copper IUD. Speculum examination revealed that both the strings of the IUD perforated the anterior lip of the cervix. Management options were offered, the patient opted for a hysteroscopic removal. We searched the electronic databases: MEDLINE, Cochrane Library, Google Scholar, EBSCO for similar cases. Results: Electronic search yielded 1821 articles; 8 were selected for inclusion. Mean age of the women was $35,37 \pm 7,781$, range (26-47) years. One woman (12,5%) was nulligravida; 3 women were multigravida (37,5%). Seven women (87,5%) were asymptomatic. Three IUDs (37,5%) were LNG-IUS; 5 IUDs (62,5%) contained copper. Conclusions: Cervical perforation by the strings of IUD is an extremely rare clinical entity. It is asymptomatic in general and in most cases the strings of the IUD may be returned back to the endocervical canal after surgical maneuvers.

Keywords: Intrauterine device; cervical perforation; hysteroscopy; copper; strings

1. Introduction

The intrauterine device (IUD) is a widely used method of contraception. It is reliable when inserted by professional health providers. [1]. It is widely accepted that the use of IUD is increasingly recommended and their use is growing universally [2]. Since their introduction, intrauterine devices (IUDs) have been related with severe but infrequent complications such as uterine perforations, pelvic infections and migration into the peritoneal cavity or adjacent organs [3]. Cervical perforations, have been mainly caused by the vertical arm of IUDs, which can be seen protruding through the cervical mucosa into one of the vaginal fornices [3,4]. An essential component of the IUDs are their strings which ensure verification of their presence in the uterus by inspecting or palpating the external cervical os. The strings assist in the safe removal of the devices in office environment. The most common problems related to the strings are missing or lost threads. The most common reasons for strings to be missing are retraction of the strings into the cervix or uterus, translocation of the device by perforation, and expulsion of the device [5].

Cervical perforation by the strings of an IUD is a very rare complication with scarce reports in the medical literature dating since the end of 1970s and the beginning of 1980s caused by Copper and Lippes loop devices [6,7]. Aim of the current study is to present a

novel case of cervical perforation by the strings of a copper IUD and to perform a systematic review of the available literature regarding this rare clinical condition.

2. Case report

The patient a 43-year-old gravida 3 para 3 attended the family planning clinic in order to remove her copper intrauterine device (IUD)-Monalisa NTCU 380 Normal manufactured by (Mona Lisa NV Belgium 2019). The IUD has been inserted 16 months previously. This was the second IUD inserted, the woman delivered with 3 Cesarean sections and used a previous copper IUD for 4 years. The patient reported headaches and galactorrhea, her prolactin levels were high, thus a recommendation of the Endocrinologist was to be subjected to a MRI (Magnetic resonance imaging) of the hypophysis in order to exclude a possible prolactinoma. The patient expressed the desire to have her coil removed in order to undergo MRI. She attended our clinic 14 days ago and underwent an annual check including colposcopy-due to LGSIL (Low grade squamous intraepithelial lesion) detected in pap smear, cervical swabs and transvaginal scan were also done. A colposcopy was performed and a cervical biopsy was obtained, transvaginal scan revealed an IUD in situ with the strings protruding through the cervical os (**fig.1**). At the time of presentation for removal of IUD two weeks after the patient reported no symptoms. On speculum examination the observation of cervix revealed that both the strings of the IUD perforated the anterior lip of the cervix at 2 o'clock, 15 mm left from the cervical os (**fig2**). Transvaginal ultrasound revealed an IUD located properly in the uterine cavity. The patient reported that she did not experience sexual contacts neither she had heavy physical duties during the past 2 weeks. Management options were offered to the patient and she opted for a hysteroscopic removal under general anesthesia. The patient was placed in a lithotomy position and local disinfection of the vagina with povidone iodine was accomplished. Diagnostic hysteroscopy with a 3 mm rigid hysteroscope and 30° oblique view (Karl Storz, Tuttlingen, Germany) revealed the presence of an IUD located correctly within the uterine cavity while the direction of strings was noticed to deviate left towards the cervical wall. A dilation of the cervix was performed and removal of the IUD with the use of a Foerster sponge forceps was achieved. The IUD was intact, further cavity observation revealed no signs of uterine perforation, a small shallow gap on the anterior wall was observed due to IUD placement. IUD was sent for culture analysis which was negative, final transvaginal ultrasound examination exhibited a normal uterus. The woman recovered successfully with no further complains. A written and signed informed consent for reporting this case was obtained from the patient. The case report was written in accordance with CARE (CAse REport) guidelines for writing a case report <https://www.care-statement.org/> [8].

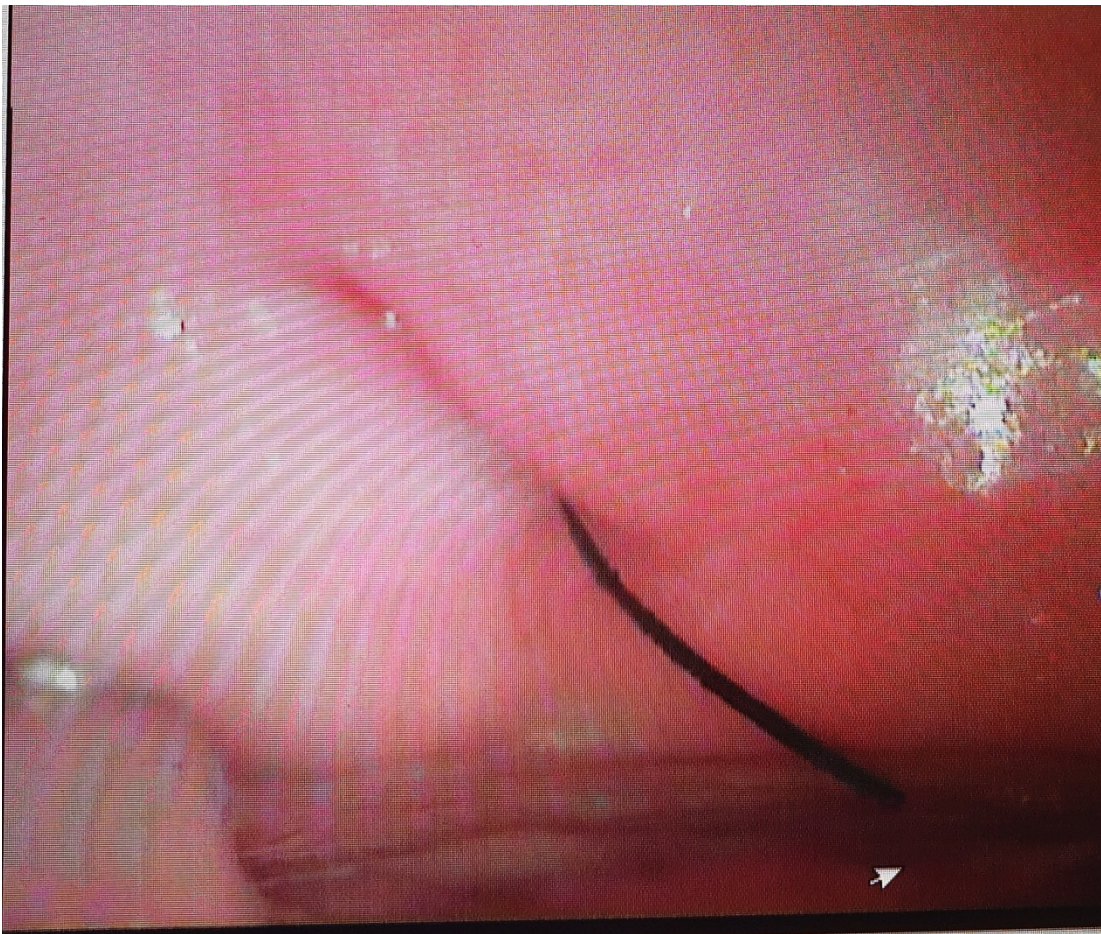

Fig.1 Image of IUD threads protruding through cervical os.

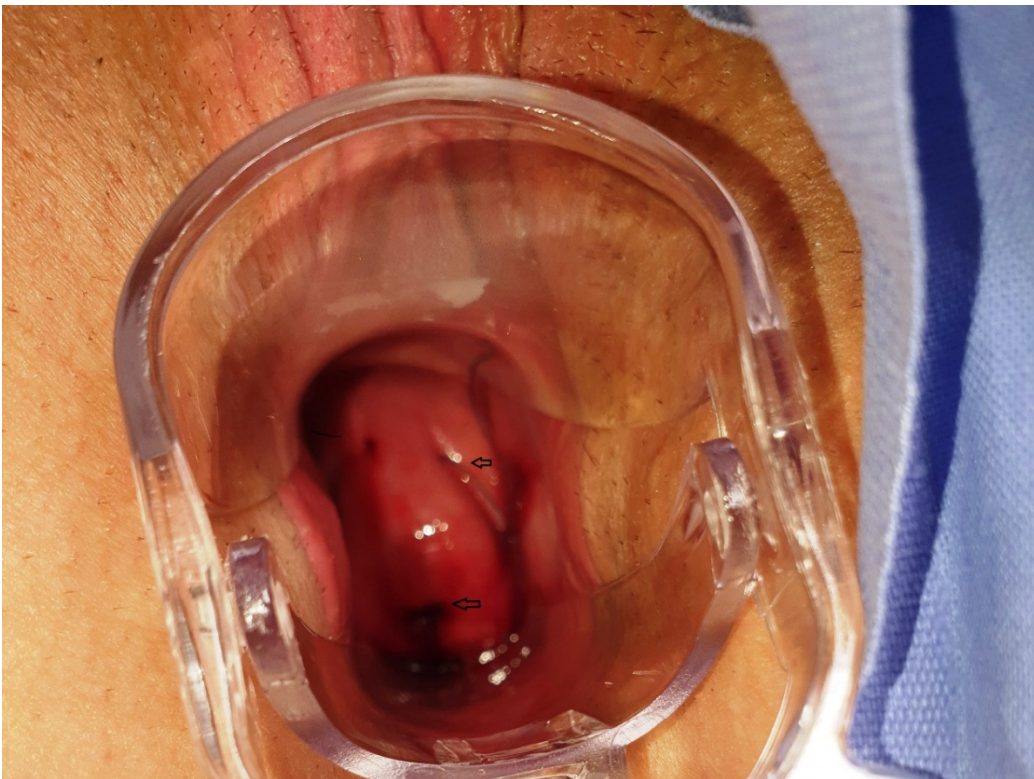


Fig.2 Image of IUD threads perforating the cervix.

3. Material and Methods

3.1. Search strategy

We searched the electronic databases: **MEDLINE** (1950– 2022), **Cochrane Library** (2004– 2022), **Google Scholar** (2000-2022), **EBSCO** (1984-2022) and no year and language restrictions were imposed. The search included the following medical subject headings (MeSH) or keywords: ‘Cervical perforation’ AND ‘IUD’ AND ‘Intrauterine device’ AND ‘Strings’ AND/OR ‘Threads’ . The last search was updated on 22/02/2022. The flowchart diagram of the systematic review was drawn according to the Preferred Reporting Items for Systematic Reviews and Meta-analyses statement (PRISMA-2020) <http://prisma-statement.org/prisma-statement/flowdiagram.aspx> [9]. The references of the selected articles were scrutinized for studies not revealed by the initial electronic search.

3.2. Eligibility criteria

The inclusion criteria were the following: Studies-case reports that reported perforation of the cervix by strings or threads of IUDs. Studies reporting perforation of cervix or uterus and any other pelvic organ by IUDs were excluded from the review.

3.3. Data extraction

Two authors (PP and CE) independently extracted the clinical data, while DS and SZ checked and tabulated the obtained information. PT checked the results and approved the study. From each eligible study, we extracted and tabulated on a Excel spreadsheet (v16.0-2016) the following clinical items of the patients included in the analysis: Author and year; Country and city; the setting of the study; the age of patient; the gravidity; the symptoms of the patient; the type of IUD inserted; the time since insertion of IUD; the location of the area of cervical perforation; the performance of ultrasound; the interventions that were used and the outcomes of the case reports-studies. We performed a quality assessment of case report according to CARE guidelines as previously mentioned⁸. A series of histograms were drawn to exhibit the quality assessment of the 13 items that should be included when writing a case report.

3.4. Statistical analysis

We conducted a calculation of the frequencies of the extracted clinical items, mean numbers, standard deviations-SD and ranges. Analysis was performed with the statistical package SPSS 23 (Statistical Package for the Social Sciences-Chicago 2015).

4. Results

Initial electronic search yielded 1821 relevant articles. The flowchart diagram of study selection is exhibited in **fig.3**. Finally of those 1821 articles after assessment and removal of duplicates 8 were selected for inclusion in the review, all case reports. In total 8 patients were enrolled in the review. Articles dated from April of 1977 to October of 2018 and all were written in English [6,7,10,11,12,13,14,15].

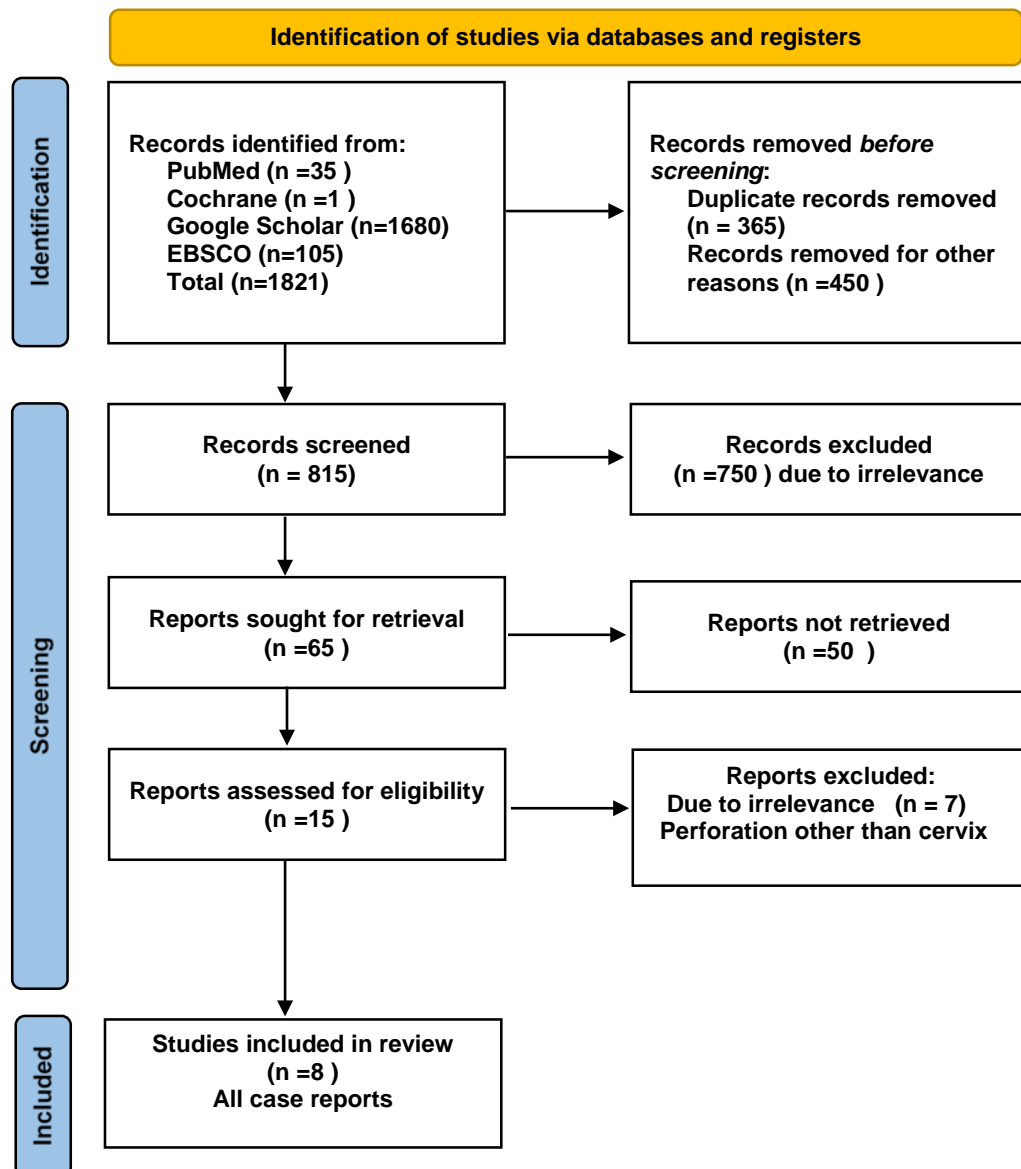


Fig.3 Prisma Flowchart diagram of study selection.

Case reports

The clinical data regarding the case reports of the systematic review are exhibited in **table 1**. Four of the case reports were published from United Kingdom [6,11,12,15] ,1 from USA [7],1 from India [10],1 from Turkey[13]and 1 from Canada [14] . All the case reports took place in University hospitals [6,7,10,11,12,13,14] apart from one case report which took place in a district hospital [15].The mean age of the women enrolled in the review was $35,37\pm 7,781$ SD (standard deviation), range (26-47) years. All women were

premenopausal; 1 woman (12.5%) was nulligravida[14]; 3 women were reported as multigravida (37,5%) [6,13,15] . Seven women (87,5%) were asymptomatic scheduled for routine check [6,7,10,11,12,13,15]; 1 woman (12.5%) attended the clinic requesting removal of IUD due to hormone-related acne possibly elicited by LNG-IUS(levonorgestrel-intrauterine system)[14] .Three IUDs (37,5%) were LNG-IUS (levonorgestrel-intrauterine system)[12,13,14]; 5 IUDs (62,5%) contained copper [6,7,10,11,15]; 1 IUD (12,5%) was Lippes loop[6] and 1 IUD (12,5%) was Gynefix[11].

Mean months since the insertion of the IUD in the 8 cases (100%) were $26,00 \pm 24,00$ SD(standard deviation),range (1-72) months. In 7 cases (87,5%) the area of perforation was located in the anterior fornix [6,7,11,12,13,14] and 1 case (12,5%) the area of perforation was located in the posterior fornix [10].The distance between cervical os and the area of perforation of strings was reported in 7 case reports ;the mean distance was $9,78 \pm 4,94$ mm SD (range 5-20 mm) [6,7,10,12,13,14,15].

In 5 cases (62,5%) TVS (transvaginal ultrasound) showed that IUD was in situ (within the uterine cavity) [10,11,13,14,15]. In 6 cases (75 %) the IUD was removed after the cervical perforation [6,7,10,12,14, 15] and in 3 cases(37,5 %) IUD remained in situ with the strings returned back at the cervical os [11,12,13] .In 1 case (12,5%) the IUD was removed and replaced with a new one [12] .General anesthesia and cervical dilation were performed in 1 case (12,5%) [15].

Author year	Country City	Setting	Age	Gravidity	Symptoms	Type of IUD	Time since insertion	Area of perforation	Ultrasound IUD position	Interventions	Outcomes
Sparks [6] 1978	UK Southampton	University Hospital	32	multigravida	Asymptomatic routine check	Lippes loop Copper	72 mts	Anterior 7.5 mm from cervical os	No	Removal	Uneventful removal
Silverman [7] 1980	USA Los Angeles	University Hospital	33	G1	Asymptomatic routine check	Copper	1 mts	Anterior 6 mm from cervical os	No	Removal	Uneventful removal
Savardekar [10] 2005	India Mumbai	University Hospital	26	G3	Asymptomatic routine check	Copper	15 mts	Posterior 20 mm from cervical os at 5 o'clock	Yes in situ	Removal	Uneventful removal
Oswal [11] 2008	UK Luton	University Hospital	35	G3	Asymptomatic routine check	Gynefix Copper	12 mts	Anterior left from cervical os	Yes in situ	Spontaneous return of strings to cervical os	IUD remained
Gbolade [12] 2010	UK Leeds	University Hospital	44	G2	Asymptomatic routine check	LNG-IUS	48 mts	Anterior 10 mm from cervical os	No	Removal with forceps	IUD removed and replaced
Gonenc [13] 2013	Turkey Istanbul	University Hospital	47	multigravida	Asymptomatic routine check	LNG-IUS	36 mts	Anterior 5 mm from cervical os at 3 o'clock	Yes in situ	Strings removed to cervical os with Novak instrument	IUD remained
Norman [14] 2014	Canada Vancouver	University Hospital	26	nulligravida	Syntomatic routine check	LNG-IUS	12 mts	Anterior 10 mm from cervical os	Yes in situ	Removal with ring forceps	Uneventful removal
Boog [15] 2018	UK Leicester	District Hospital	40	multigravida	Asymptomatic routine check	Copper T	12 mts	Anterior 10 mm from cervical os at 1 o'clock	Yes in situ	Removal with Spencer-Wells forceps under GA	Uneventful removal

Table 1. Table summarizing the case reports regarding perforation of cervix by IUD threads.

Quality of case reports

The quality of case reports was performed according to the criteria of CARE guidelines [8] ; CARE criteria consist of 13 items, as shown in the **fig.4**. Poor quality was detected in item 12 with a percentage of 100 % followed by item 1 and 13 with a percentage of 60 % respectively. Moreover low quality was detected in the items 5c,5d,9a with a percentage of 30 %. In items 8d,9c,10a,10c low quality was detected with a percentage of 20 % .

Topic	Item	Checklist Item description	Percentage of evaluation
Title	1	The diagnosis or intervention of primary focus followed by the words "case report".	
Key words	2	2 to 5 key words that identify diagnoses or interventions in this case report.	
Abstract	3a	Introduction: What is unique about this case and what does it add to the scientific literature?.	
	3b	Main symptoms and/or important clinical findings	
	3c	The main diagnoses, therapeutic interventions, and outcomes.	
	3d	Conclusion—What is the main "take-away" lesson(s) from this case?.	
Introduction	4	One or two paragraphs summarizing why this case is unique (may include references).	
Patient Information	5a	De-identified patient specific information	
	5b	Primary concerns and symptoms of the patient.	
	5c	Medical, family, and psycho-social history including relevant genetic information	
	5d	Relevant past interventions with outcomes	
Clinical Findings	6	Describe significant physical examination (PE) and important clinical findings	
Timeline	7	Historical and current information from this episode of care organized as a timeline	
Diagnostic	8a	Diagnostic testing (such as PE, laboratory testing, imaging, surveys).	
Assessment	8b	Diagnostic challenges (such as access to testing, financial, or cultural)	
	8c	Diagnosis (including other diagnoses considered)	
	8d	Prognosis (such as staging in oncology) where applicable.	
Therapeutic	9a	Types of therapeutic intervention (such as pharmacologic, surgical, preventive, self-care)	
Intervention	9b	Administration of therapeutic intervention (such as dosage, strength, duration)	
	9c	Changes in therapeutic intervention (with rationale)	
Follow-up and	10a	Clinician and patient-assessed outcomes (if available)	
Outcomes	10b	Important follow-up diagnostic and other test results	
	10c	Intervention adherence and tolerability (How was this assessed?).	
	10d	Adverse and unanticipated events	
Discussion	11a	A scientific discussion of the strengths AND limitations associated with this case report	
	11b	Discussion of the relevant medical literature with references	
	11c	The scientific rationale for any conclusions (including assessment of possible causes)	
	11d	The primary "take-away" lessons of this case report in a one paragraph conclusion	
Patient Perspective	12	The patient should share their perspective in one to two paragraphs on their treatment(s)	
Informed Consent	13	Did the patient give informed consent? Please provide if requested	
			10% 20% 30% 40% 50% 60% 70% 80% 90% 100%

Table 2. Quality of case reports according to CARE guidelines.

5. Discussion

This is the ninth reported case of cervical perforation by the strings of IUD in the international literature and the first to be removed under hysteroscopic intervention. Our systematic review showed that the phenomenon of cervical perforation by the strings of IUD is an asymptomatic clinical entity without local irritating effects.

Cervical perforation was reported more often in Copper IUDs (62.5%) [6,7,11,12,13,14] vs LNG-IUS (37.5%) [12,13,14]. Perforation of the anterior cervical fornix is the most common place where the strings have been located [6,7,11,12,13,14].

In our case it was diagnosed incidentally 2 weeks after the last clinical examination. Cervical perforation may be diagnosed 26 months after insertion as it was found in our analysis. The incidence of cervical perforation from IUDs ranges from 0.2 to 1.3% [16].

What is the pathophysiological mechanism that leads to this phenomenon and how the strings are transferred from the cervical os and how they perforate the cervical tissue?

There is a hypothesis reported by Gbolade [13] which mentions that it is unlikely that the iron oxide and polyethylene composition of the strings of the levonorgestrel-releasing intrauterine systems makes them sufficiently rigid to perforate the cervical lip. Thus, the two most plausible explanations for this occurrence are the development of a fistulous tract caused by the single-toothed tenaculum used at the time of insertion, providing a canal for the string(s), or a laceration of the cervix caused [13]. The author suggests that less traumatic forceps such as Teales curved vulsellum (3:4 teeth) should be used for the insertion of IUDs; however the author mentioned that no trauma was caused in the cervix during the insertion in his case [13]; similarly in our case we did not record any trauma at the time of insertion.

Another scenario is the following: the mechanism whereby the threads of an intrauterine contraceptive appear to have perforated the cervix may result from their penetrating the epithelium (and the stroma) like setons (which have been used for more than 2000 years to treat fistulae) and then working their way through tissue. When a thread or a thin tube is passed through a fistulous tract and then tied to form a loop which is tightened at intervals, it will progressively cut through tissue while, simultaneously, the divided tissue behind it heals, resulting in the release of the seton [13].

What is the management of this condition? In general it is advisable to return the strings back to the endocervical canal via the use of several instruments. Ultrasound definitely will define the correct positioning of IUDs in the uterine cavity, so every intervention should be done under sonographic guidance. Our review showed that in 5 cases (62,5%) the IUD was correctly positioned. In case it is not feasible return of the strings into the canal and there is suspicion of penetration by the IUD, removal should be utilized via office or conventional hysteroscopy.

Our review has limitations due to the small number of included case reports however is the first systematic review performed in the literature.

6. Conclusion

Cervical perforation by the strings of an IUD is an extremely rare clinical entity. In general is asymptomatic and affects the anterior lip of cervix. It occurs mainly in multigravida women and it may be diagnosed after 2 years since the initial insertion. It may cause frustration to the clinical professional and the patient as well. The pathogenesis of this phenomenon is not explained completely and more studies are required to be reported. In most cases the strings may be returned back to the endocervical canal successfully.

Author Contributions: Conceptualization and original draft preparation, P.P.; project administration, C.E.; writing—review and editing, P.P,C.E,D.S.; supervision, S.Z,P.T.; All authors have read and agreed to the published version of the manuscript. **Funding:** This research received no external funding.

Institutional Review Board Statement: This study was approved by Institutional Review Board of Rea Hospital.

Informed Consent Statement: Written informed consent has been obtained from the patient(s) to publish this paper if applicable.

Data Availability Statement: Not applicable.

Acknowledgments: We are grateful to all of those we worked together in similar projects.11

Conflicts of Interest: The authors declare no conflict of interest.

Disclosure statement: The authors report there are no competing interests to declare.

References

1. Glasier A. Contraception. In: Edmonds KD, ed. Dewhurst's Text-book of Obstetrics and Gynaecology , 7 th edition. Maldon, MA:Blackwell Publishing, 2007:299–317
2. Dunn S, Anderson GM, Bierman AS; POWER Study. Temporal and regional trends in IUD insertion: a population-based study in Ontario, Canada. *Contraception* 2009;80(5):469–73.
3. Paulson J D , Kao M S. Cervical perforation by the copper-7 intrauterine device . *Obstet Gynecol* 1977 ; 50 : 621 – 2 .
4. Koltan S O, Tamay A G, Yildirim Y . Chronic cervical perforation by an intrauterine device. *J Chin Med Assoc* 2010 ; 73 : 325 – 6 .
5. Johnson BA. Insertion and removal of intrauterine devices. *Am Fam Physician* 2005;71(1):95–102.
6. Sparks RA. Problems with IUCD tails. *Br Med J*. 1978 Apr 29;1(6120):1141
7. Silverman I, Rubinstein LM. Perforation of the exocervix by an IUD tail.*Contracept Deliv Syst* 1980;1:369–70.
8. Riley DS, Barber MS, Kienle GS et al. CARE guidelines for case reports: explanation and elaboration document. *J Clin Epidemiol*. 2017 Sep;89:218-235.
9. Page MJ, McKenzie JE, Bossuyt PM, et al. The PRISMA 2020 statement: an updated guideline for reporting systematic reviews. [BMJ 2021;372:n71.](#)
10. Savardekar LS, Shah RS, Vandana W. Asymptomatic cervical perforation by intrauterine copper bearing contraceptive device: two unusual cases. *Eur J Obstet Gynecol Reprod Biol*. 2005 Jun 1;120(2):236-7.
11. Oswal A, Loizides S, Robinson C. Gynefix tales: cervical perforation and repeated late expulsion with the Gynefix device. *Eur J Contracept Reprod Health Care*. 2008 Jun;13(2):215-7.
12. Gbolade BA. Perforation of the cervix by the threads of a levonorgestrel-releasing intrauterine system: a case report. *J Womens Health (Larchmt)*. 2010 Dec;19(12):2277-9.

-
13. Gönenç I, Vural EZ, Aka N. Cervical perforation by the strings of a levonorgestrel releasing-intrauterine system: a case report. *Eur J Contracept Reprod Health Care*. 2013 Oct;18(5):415-8.
 14. Norman WV, Stothart D. IUD String Perforation Through Anterior Cervix: A Case Report. *J Obstet Gynaecol Can*. 2015 Apr;37(4):345-348. doi: 10.1016/S1701-2163(15)30285-1.
 15. Boog K, Kumar V. Perforation of the anterior cervix by the threads of an intrauterine device. *BMJ Sex Reprod Health*. 2018 Oct;44(4):314-315.
 16. Prema K, Malhotra U, Choudhary SD et al. Uterine perforations with Copper T IUDs. *Contracept Deliv Syst* 1981;2:327–9.