

Article

Is it all about Surface Topography? An Intraindividual Clinical Outcome Analysis of Two Different Implant Surfaces in Breast Reconstruction

Ines Schoberleitner ^{1,✉}, Angela Augustin ^{1,✉}, Daniel Egle ², Christine Brunner ², Birgit Amort ³, Bettina Zelger ⁴, Andrea Brunner ⁴ and Dolores Wolfram ^{1,*}

¹ Department of Plastic, Reconstructive and Aesthetic Surgery; Medical University of Innsbruck, Anichstraße 35, A-6020 Innsbruck

² Department of Obstetrics and Gynecology; Medical University of Innsbruck, Anichstraße 35, A-6020 Innsbruck

³ Department of Radiology; Medical University of Innsbruck, Anichstraße 35, A-6020 Innsbruck

⁴ Institute of Pathology, Neuropathology and Molecular Pathology; Medical University of Innsbruck, Müllerstraße 44, A-6020 Innsbruck

✉ These authors contributed equally to this work

* Correspondence: dolores.wolfram@i-med.ac.at; Tel.: +43 512 504 82050

Abstract: The most common long-term complication of silicone breast implants (SMI) remains capsular fibrosis. The etiology of this exaggerated implant encapsulation is multifactorial but primarily induced by the host response towards the foreign material silicone. Identified risk factors included specific implant topographies. Of note, breast implant-associated anaplastic large cell lymphoma (BIA-ALCL), has only been observed in response to textured surface implants. We hypothesize that reduction of SMI surface roughness causes less host response hence better cosmetic outcome with fewer complications for the patient. A total of 7 patients received the routinely used CPX®4 breast expander (~60 μM Ra) and the novel SmoothSilk® (~4 μM Ra), fixed prepectoral with a titanised mesh pocket and randomized to the left or right breast after bilateral prophylactic NSME (nipple-sparing mastectomy). We aimed to compare the postoperative outcome regarding capsule thickness, seroma formation, rippling, implant dislocation as well as comfortability and practicability. Our analysis shows that surface roughness is an influential parameter in controlling fibrotic implant encapsulation. First time intra-individually compared in patients, our data confirm an improved biocompatibility with minor capsule formation around SmoothSilk® implants with an average shell roughness of 4 μM and in addition an amplification of host response by titanised implant pockets.

Keywords: nipple-sparing mastectomy; prophylactic implant-based breast reconstruction; SMI (silicone mammary implants); SMI surface topography; surface roughness; fibrosis; capsular contraction; aesthetic outcome; intra-individual comparison; titanised mesh implant pocket

1. Introduction

Breast augmentation with silicone mammary implants (SMI) is one of the most performed procedures in aesthetic surgery. According to the American Society of Plastic Surgeons (ASPS), officially, almost 200,000 breast augmentations were performed in the United States in 2020 [1] and current conservative estimates suggest that more than 35 million women worldwide have textured breast implants [2]. Since breast cancer is the most common cancer in females worldwide [3] and due to increasing numbers of women diagnosed with and surviving breast cancer, it is critical to stay acquainted with breast reconstructive trends. Despite significant advances in screening, diagnostic, and cancer therapies the total mastectomy numbers remain high [4]. Breast reconstruction after mastectomy has a significant positive impact on the long-term body image, quality of life, and psychological health of affected women [5, 6]. Despite clear evidence of superior long-

term satisfaction after autologous breast reconstruction, the US, as well as Europe, have experienced a clear shift towards implant-based breast reconstruction. As of 2002, implants surpassed autologous techniques as the most common method of breast reconstruction in the US [7]. The benefits of implant-based reconstruction are its ease of technique, faster recovery, and avoidance of donor-site morbidity, but autologous techniques have proven to be superior in terms of long-term quality of life and aesthetic outcome [8–11].

Therefore, the motivation is high to continuously refine the technique of implant-based breast reconstruction to meet high aesthetic demands. Immediate two-stage expander (inflatable SMI)-based breast reconstruction is, according to the American Society of Plastic Surgeons (ASPS), still the most commonly chosen technique [12]. With this technique a partially filled tissue expander is placed first and, in a second stage after several months and completion of pocket formation, an exchange for a permanent implant is conducted. This approach allows to offload of initial pressure on the potentially compromised mastectomy skin flap and it allows the selection of the ideal permanent implant following an expansion period as well as to correct the implant pocket during the second stage [13–15].

Silicone is the implant material (i.e., foreign body) most widely used in routine medical practice. However, local and systemic complications in SMI carriers are still frequently reported and are controversially discussed in the literature [16–29]. The most common complication of SMI is fibrotic-implant encapsulation and peri-SMI capsular contracture, with a reported incidence from 0.5% to 50% [26, 27, 29, 30]. The resulting clinical symptoms are pain, local tissue damage, and an unpleasing aesthetic outcome. This high variability of reported capsular contracture rates depends on many factors: different periods, types of implants used, implant locations, and others such as “defensive reporting” [17, 19–21].

After device implantation, mechanisms of foreign body response (FBR) induce, fibrosis, an excessive formation of collagenous and non-collagenous extracellular matrix (ECM) components in organs and tissues, as a reparative or reactive process [31], mainly due to the proliferation and activation of fibroblasts and myofibroblast. There is a considerable amount of evidence highlighting fibrosis as a result of complex and sequential chronic inflammatory reactions induced by various stimuli (e.g., persistent infections, autoimmune reactions, allergic responses, chemical insults, radiation, and tissue injury) [32–40].

According to the International Organization for Standardization (ISO), 14607:2018 implants can be discriminated by a classification system based on surface topography according to surface roughness (Ra) determination by scanning electron microscopy (SEM) [41]. According to this classification, SMI surfaces are designated as smooth ($Ra < 10 \mu\text{m}$), microtextured ($10 \mu\text{m} \leq Ra \leq 50 \mu\text{m}$), or macrotextured ($Ra > 50 \mu\text{m}$). Clinical studies suggest that these different surface architectures induce different foreign body immune responses and fibrosis [2, 42–50]. Higher surface texture complexity leads to increased capsule disorganization, tissue ingrowth, and adherence, therefore textured implants show a lower risk of malposition or rotation [51–53]. Importantly, macrotextured prostheses showed a higher risk of biofilm formation and they have been associated with the occurrence of anaplastic large cell lymphoma (BIA-ALCL) [54–58]. Due to the BIA-ALCL topic, the impact of surface roughness has gained immense popularity and sales numbers of breast implants in the US show a clear shift toward smoother devices. Therefore, currently, microtextured tissue expanders are widely used, but also within this group surface roughness may vary widely. Zhang et al. showed an increase in collagen formation and fibroblast formation but a decreasing expression of inflammation cytokines with higher surface roughness in the capsule surrounding the implant in a rat model [59]. In a previous approach, we investigated the immune response of human peripheral blood mononuclear cells (PBMC) to commercially available silicone surfaces (breast implant surfaces) *in vitro* and could demonstrate that a decrease in surface topography reduces adherent immune cells and fibrosis-associated cytokine gene expression [46]. Correspondingly, recent *in vivo* studies of implants with various topographies showed that the SmoothSilk®

surface (Motiva® Flora), with an average roughness of 4 μM , provokes the least amount of inflammation and foreign response in the rat model [45].

Hence, although tissue expanders are designated to be removed and exchanged for definite implants, their impact on the prosthesis environment must be considered beyond their period of use. Comparative studies on the clinical outcome of implant reconstruction after the use of different types of tissue expanders are scarce and they mainly focus on the evaluation of complications such as malposition, seroma formation, infections, capsular contracture, and reoperation rates [53, 60–62]. In prior investigations, we analyzed the composition of peri-SMI connective tissue capsules only in women who received such implants for aesthetic reasons [31, 63, 64].

We hypothesize that the choice of the expander during the first operative stage may have a permanent impact on the final reconstructive result due to surface-depending tissue imprinting of the created pocket. Patients undergoing a prophylactic mastectomy followed by breast reconstruction are an ideal cohort for cellular and molecular immunological elucidation of fibrosis due to their uncompromised health status and immune system, contrary to patients with implant-based reconstruction after invasive breast cancer.

We, therefore, aimed to conduct the first intraindividual comparison and interindividual evaluation of two different tissue expanders with varying surface topography roughness by comparing the aesthetic and patient-reported outcome as well as conducting a histopathological and radiographic evaluation of the capsule after tissue expander reconstruction with 60 μM Ra (CPX®4 breast, MENTOR®, USA) vs 4 μM Ra (Smooth-Silk®, Motiva Flora®, Establishment Labs, Costa Rica) average surface roughness.

In immediate two-stage breast reconstruction, the expander is positioned in the submuscular/subcutaneous plane combined with a mesh pocket for fixation to the *pectoralis major*. Implantation of a mesh triggers a foreign-body reaction, which plays a crucial role in the incorporation of the mesh into the host tissue. By histological comparison, we opted to evaluate the potential immunoreactivity and intracapsular incorporation of Titanium-coated Polypropylene meshes.

Our data confirm, an improved surgical outcome of a reduced implant surface topography in humans - with minor capsule formation. Moreover, we demonstrate clear amplification of foreign body response by Titanium-coated implant pocket in early-stage fibrosis.

2. Materials and Methods

Study population

This study included a total of 7 female patients with high familial risk for breast cancer, who were undergoing simultaneous prophylactic bilateral nipple-sparing mastectomy (NSME) and immediate tissue expander-based breast reconstruction. Informed consent for photo documentation, the operation, sample collection, and anonymized evaluation and publication of data was obtained in written form from all patients after confirmation of all in- and exclusion criteria (Table 1).

Patient demographics including age, body mass index (BMI) and breast size cup, breast symmetry, previous scars in breast area, comorbidities (chronic diseases, allergies, medication), dominant hand, smoking habits, profession (manual labor/ office job) and physical training habits, as well as duration, were documented. All interventions (operation, photo documentation, ultrasound, sample collection, anonymized evaluation, and publication of data) were performed, and information was obtained, with the informed written consent of the participants and in accordance with: (i) the regulations of relevant clinical research ethics committee as well as (ii) the Declaration of Helsinki and with (iii) The European Union Medical Device Regulation (§ 40 section 3 Medical Devices Act). The two different devices were randomized to the right or left breast, and patients were blinded.

Therefore 7 SmoothSilk® and 7 CPX®4 breast tissue expanders were evaluated intra- and inter-individually by patient-reported expander aesthetic and comfort outcome, Surgeon reported satisfaction with expander practicability and aesthetic outcome at informational endpoints at weeks 4, 16, and after reoperation, as well as the thickness of fibrotic capsule around expander shells.

Table 1. Inclusion and exclusion criteria for the Expander-Immunology trial.

Inclusion criteria		Exclusion criteria	
1	Female sex	1	Severe coagulation disorder, representing a potential contraindication for the elective surgery
2	Age > 18 years	2	Rheumatic disease accompanied by obligatory intake of immunomodulating therapeutic agents
3	High-risk family history for breast and/or ovarian cancer and/or BRCA1/2 gene mutation carrier	3	Severe renal functional disorder: renal insufficiency status IV or V (estimated glomerular filtration rate (GFR) < 30ml/min)
4	Planned bilateral mastectomy with simultaneous breast reconstruction	4	Active hematological or oncological disease
5	Signed informed consent form.	5	HIV-Infection
		6	Hepatitis-Infection
		7	Pregnancy or breast-feeding
		8	Intake of anti-inflammatory drugs
		9	Carrier of silicone implants (e.g. gastric banding, mammary implants)

Study design

This monocentric, randomized, double-blind controlled clinical study was approved by the Institutional Ethical Committee of the Medical University Innsbruck, Austria (protocol code 1325/2019, 23 January 2020) and the Austrian Federal Office for Safety in Health Care (approval number; 13340962). We evaluated a total of 7 patients, who received both, the routinely used expander Mentor CPX™4 and the novel Motiva SmoothSilk® with reduced surface topography roughness, randomized to the left or right breast after prophylactic bilateral NSME (Figure 1).

In the first operation, NSME was performed by gynecologists, subsequently, plastic surgeons performed the reconstructive part of the operation. Patients received within the first operation both tissue expanders (=inflatable silicone implants), namely SmoothSilk® and CPX®4, to reconstruct the breasts. The expanders were positioned in the prepectoral subcutaneous plane combined with a Titan bra (TiLOOP®) to cover the implant. Both expanders were stepwise filled during periodical follow-up care.

Clinical examinations and questionnaire evaluation. Clinical examinations addressing any side effects of the implanted tissue expanders SmoothSilk® and CPX® were performed 2 weeks, 4 weeks, 5 weeks, 6 weeks, 7 weeks, 8 weeks, and 16 weeks after the initial operation. Documentation of complications (wound dehiscence, signs of inflammation, breast structure swelling, potential expander malposition) and expander symmetry as well as palpation of the breasts was conducted. Additionally, two standardized questionnaires addressing aesthetic, practicability, and comfortability outcome satisfaction of the implant were filled out 4 weeks and 6-8 months after the expander implantation. The schedule of the follow-up examinations is demonstrated in Table 2.

Table 2. Satisfaction questionnaire – Surgeon and patient scale of device aesthetic, practicability, and comfortability, as well as satisfaction after expander-based breast reconstruction with SmoothSilk® and CPX®4.

Surgeon scale	time point post op	Numeric scale
How satisfied are you with the lower pole expansion of the expander?	6-8 months	not satisfied : 0 to 3 satisfied 4 to 7 very satisfied : 8 to 10
How satisfied are you with the footprint created by the expander?	6-8 months	
Patient scale	time point post op	
How satisfied are you with the expander?	4 weeks	not satisfied : 0 to 3 satisfied 4 to 7 very satisfied : 8 to 10
Please indicate how comfortable the expander was?	6-8 months	not comfortable : 0 to 3 comfortable 4 to 7 very comfortable: 8 to 10

Radiology. After 6-8 months, the expander was removed and a permanent silicone breast implant was placed. Directly before the expander exchange – during this hospital stay - all patients were undergoing an ultrasound examination preoperatively, performed by a radiologist, in order to analyze the thickness of the capsule formed around the expanders. Seroma formation, implant dislocation, and thickness of the capsule have been evaluated with SIEMENS 18L6HD.

Histological processing and quantification. During reoperation, capsular tissue (3x3cm) was harvested from both implants, at 2 positions, anterior contact zone with TiLOOP® and posterior (TiLOOP® free) contact zone with *M. pectoralis*. Samples fixed in formalin and routinely processed at the Institute of Pathology, Neuropathology and Molecular pathology. For histological evaluation consecutive sections stained with Hematoxylin & Eosin (H&E) and Chromotrope-anillin-blue (CAB) were compared in parallel and capsule thickness was measured at 2 places along the implant–tissue boundary for each implant at both contact zones (n = 2 per group per implant type), for duplicate sections for lower poles or sides of the implants.

Aesthetic outcome evaluation. The evaluation was conducted based on standardized photo documentation taken after the first (final filling of expander devices) and second stage (after exchange to final implant) of breast reconstruction. The evaluation was done by a gender-balanced panel of four independent plastic surgeons (two seniors, and two residents) using a German translation of the Breast Aesthetic Scale [65]. Seven questions of this validated tool were used to evaluate the aesthetic result, of both sides in all included seven patients after bilateral breast reconstruction. One further item about the symmetry of the breasts pertains to both sides and was therefore only answered once per patient and reconstructive stage. Every question is graded from 1 to 5, with 5 points representing the perfect aesthetic result.

Patients and plastic surgeons were double-blinded. Matching was performed intra-individual and conducted according to the implanted tissue expander.

Statistical analysis

Tissue expanders were randomized to either the left or right breast via a randomization list (provided by the Department for Medical Statistics and Health Economy, Medical University Innsbruck). To prevent bias, the randomization list was generated prior to the first patient enrollment. Paired student's t-test and the non-parametric Wilcoxon test for paired samples were used for normally and non-normally distributed data sets, respectively. Variance analysis was performed for repeated measurements between the two groups.

Statistical significance of the correlation matrix was determined by the Pearson correlation coefficient with a two-tailed confidence interval of 95%. Statistical significance of simple linear regression has been determined by comparison of slopes and intercepts confidence interval of 95%. (inter- and intra-individual comparison; n=7). Descriptive analysis was used to summarize patient outcome data. Statistical analyses were performed using Prism Software 9.0 (GraphPad, USA). The statistical details of experiments are presented

in the relevant figure legends. A *p*-value of < 0.05 was considered significant. The level for statistical significance was set at $p^{ns} > 0.05$, $p^* < 0.05$, $p^{**} < 0.002$, $p^{***} < 0.0002$, and $p^{****} < 0.0001$, for all statistical tests.

3. Results

3.1. Patient characteristics

Seven healthy female patients with bilateral prophylactic mastectomy and simultaneous tissue expander-based breast reconstruction, due to high-risk hereditary predisposition and/or confirmed *Brca1+/Brca2+* gene mutation, were enrolled in the study (Figure 1a). All patients received both types of expanders, the routinely used CPX®4 breast expanders (MENTOR®, USA: surface roughness: $\sim 60 \mu\text{M Ra}$) and the novel surface-roughness reduced SmoothSilk® breast expanders (Motiva Flora®, Establishment Labs, Costa Rica: surface roughness: $\sim 4 \mu\text{M Ra}$) randomized to the left or right breast after bilateral prophylactic NSME (Figure 1b, c). Patient demographic data and device information are summarized in Table 3.

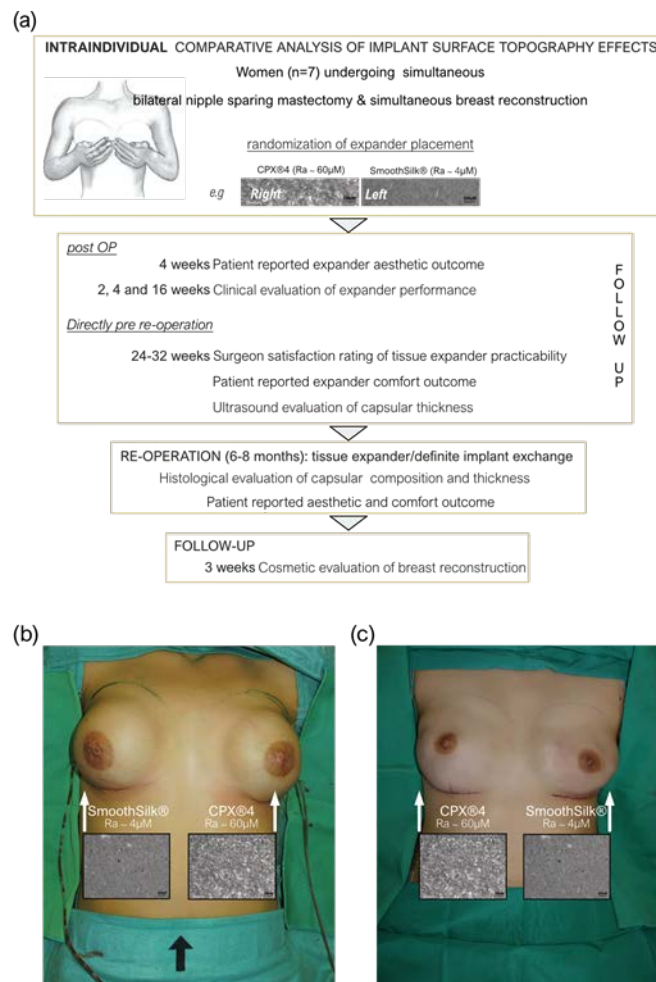


Figure 1. Expander immunology Trial. (a) Assessment schedule pre- and after-expander implantation. (b-c) Standardized intra-operative photo documentation of an intraindividual comparative bilateral tissue expander-based breast reconstruction. Each patient received both types of expanders, the routinely used CPX®4 breast expanders (MENTOR®, USA: surface roughness: $\sim 60 \mu\text{M Ra}$) and the novel surface-roughness reduced SmoothSilk® breast expanders (Motiva Flora®, Establishment Labs, Costa Rica: surface roughness: $\sim 4 \mu\text{M Ra}$) randomized to the left or right breast in combination with TiLOOP® pocket mesh after bilateral prophylactic NSME. (b) Patient 003; Right: SmoothSilk®, Left: CPX®4, (c) Patient 001; Right: CPX®4, Left: SmoothSilk®.

Table 3. Summary of patient demographic characteristics and device information.

IMPLANTATION SITE	Left: SmoothSilk® ; Right: Mentor CPX®4			Left: Mentor CPX®4 ; Right: SmoothSilk®			
	PAT 001_001	PAT 001_002	PAT 001_007	PAT 001_003	PAT 001_004	PAT 001_005	PAT 001_006
Vital parameters							
age (y)	34	41	30	31	26	60	33
weight (kg)	86,3	54	108	54	58	105	57
size (cm)	186,5	155,5	172	167	159	176	166
body mass index	24.8	22.3	36.5	19.4	22.9	33.9	20.7
body surface area	2.12	1.52	2.9	1.6	1.59	2.2	2.7
Status of natural breast							
asymmetry	no	no	no	no	no	no	no
scars	no	no	no	no	no	no	no
diseases	no	no	no	no	no	no	no
active smoker	yes	no	no	no	no	no	no
allergies	no	no	no	no	no	no	no
Chronic diseases							
diabetes	no	yes	no	no	no	no	no
Other							
job	manual job	office job	office job	office job	office job	manual job	office job
physical training (h/week)	>2	>2	0.5-2	>2	>2	0.5-2	0.5-2
dominant hand	right	right	right	right	right	right	right
1st OPERATION: tissue expander implantation							
Bilateral prophylactic NSME resection weight [g]							
right breast	449	187	980	200	400	750	208
left breast	471	167	1060	200	450	575	252
Prepectoral reconstruction volume [cc]							
Motiva Flora® SmoothSilk®	450	260	570	260	440	570	260
Mentor CPX4	440	250	550	250	450	550	250
Intra-operative filling (both devices)	250	150	550	150	300	500	150

There were no significant differences in patient characteristics, mastectomy weight, implant position (prepectoral), reconstruction volume and intraoperative filling, or time point of expander exchange between the two differently textured devices (Table 4).

Table 4. Intraindividual statistical comparison of analytical groups.

surface roughness	SmoothSilk® Ra ~ 4 µM		MentorCPX®4 Ra ~ 60 µM		p value
	mean	± SD	mean	± SD	
age (y)	35.2	11.4	35.2	11.4	intraindividual comparison >0.9999
weight (kg)	71.4	24.5	71.4	24.5	
size (cm)	168.6	10.5	168.6	10.5	
body mass index	25.1	6.7	25.1	6.7	
Bilateral prophylactic NSME resection weight [g]					
left breast	434.9	404.0	436.9	454.0	0.993196
right breast	334.2	257.5	337.9	174.4	0.975407
Prepectoral reconstruction volume [cc]					
left breast	405.5	156.3	392.6	151.8	0.877595
right breast	360.8	151.1	352.7	150.0	0.920737
intra-operative filling [ml]	254.7	169.4	254.7	169.4	intraindividual comparison >0.9999
exchange time point [d]	204.8	25.8	204.8	25.8	

As presented in Figure 2, the mastectomy weight of the left and right breast correlated bilaterally with high significance in all 7 subjects (Figure 2a, ***p=0.005). Moreover, the mastectomy weight of both breasts correlated and increased in dependence with BMI (Figure 2b, right breast: ***p=0.0002, left breast: **p=0.006). Postoperatively, the tissue expander intermediate expansion volume correlated bilaterally within, but also with BMI as well as the weight of the mastectomized breast, in a simple regression respectively. The final implant reconstruction volume correlated bilaterally with the mastectomy weight as well as with the intermediate expander volume, but not to BMI (Figure 2e-f).

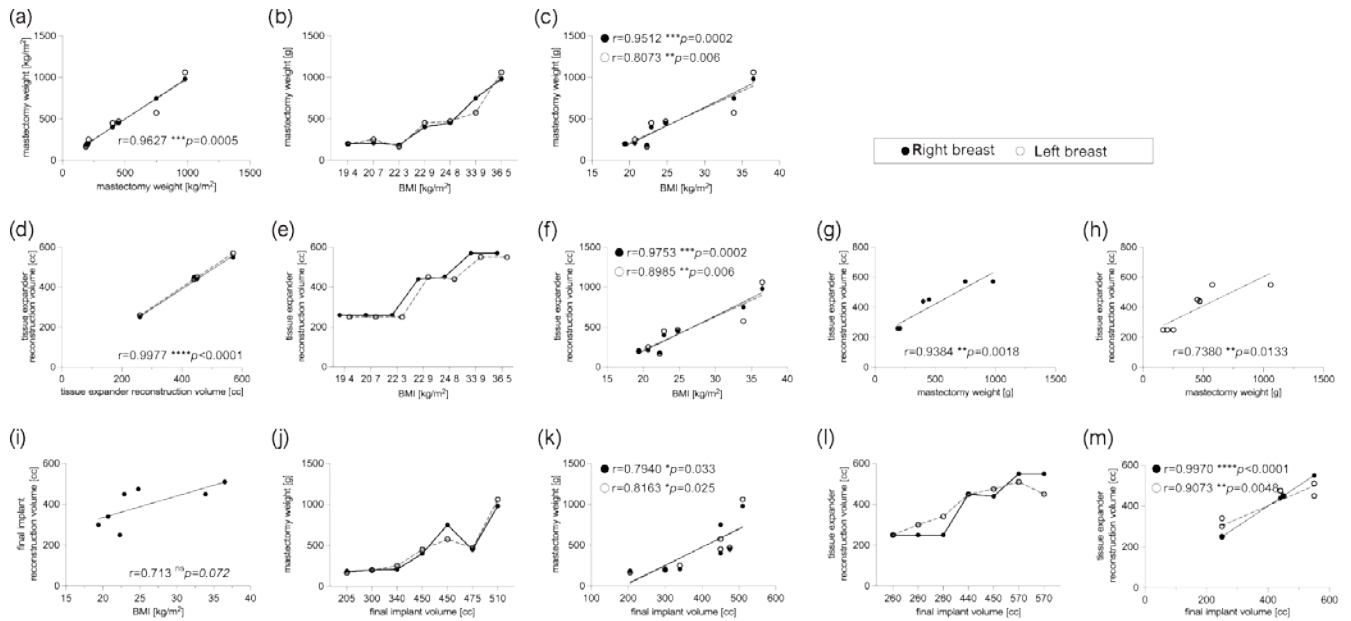


Figure 2. Intra-individual comparison of mastectomy weight, tissue expander reconstruction volume, and final implant volume. (a) Bilateral correlation of mastectomy weight obtained from left and right breast. (b) Mastectomy weight correlates (c) in a simple regression with BMI (R: $w^{\text{mast}} = 44.66 \cdot \text{BMI} - 698.2$, L: $w^{\text{mast}} = 41.38 \cdot \text{BMI} - 613.4$). (d) Bilateral correlation of tissue expander reconstruction volume obtained from left and right breast. (e) Tissue expander reconstruction volume correlates (f) in a simple regression with BMI (R: $V_{\text{TE}} = 1 \cdot \text{BMI}$; L: $V_{\text{TE}} = 0.9585 \cdot \text{BMI} - 1.352$) as well as (g-h) weight of corresponding mastectomized (g) right and (h) left breast. (i) Final implant reconstruction volume correlation with BMI (ns). (j) Final reconstruction volume correlates bilaterally (k) in a simple regression with the weight of corresponding mastectomized breast BMI (R: $V_{\text{SMI}} = 1 \cdot w^{\text{mast}}$; L: $V_{\text{SMI}} = 0.6528 \cdot \text{BMI} - 140.9$) as well as (l-m) with corresponding tissue expander reconstruction volume (R: $V_{\text{TE}} = 1 \cdot w^{\text{mast}}$; L: $V_{\text{TE}} = 0.6528 \cdot \text{BMI} - 140.9$). Statistical significance of the correlation matrix has been determined by the Pearson correlation coefficient with a two-tailed confidence interval of 95%. Statistical significance of simple linear regression has been determined by comparison of slopes and intercepts confidence interval of 95%. The level for statistical significance was set at $p_{\text{ns}} > 0.05$, $p^* < 0.05$, $p^{**} < 0.002$, $p^{***} < 0.0002$, and $p^{****} < 0.0001$, for all statistical tests. (inter- and intra-individual comparison; $n=7$).

3.2. Clinical evaluation of expander performance

After NSME & expander insertion, clinical examinations were performed 2 weeks, 4 weeks, and 16 weeks post-op. Wound dehiscence, signs of inflammation, symmetry, breast structure swelling, expander malposition, and palpation were clinically evaluated and documented (Table 5).

Table 5. Clinical evaluation of tissue expander performance 2W, 4W, and 16W post-device implantation.

		SmoothSilk® Ra ~ 4 µM	MentorCPX®4 Ra ~ 60 µM	
surface roughness				
Postoperative complications				
	time point post op	n (%)	n (%)	p value
wound dehiscence	2W, 4W, 16W	0 (0%)	0 (0%)	>0.9999
inflammation	2W, 4W, 16W	0 (0%)	0 (0%)	
breast structure swelling	2W, 4W, 16W	0 (0%)	0 (0%)	
expander malposition	2W, 4W, 16W	0 (0%)	0 (0%)	
Palpation				
	time point post op	n (%)	n (%)	p value
firm	2W, 4W, 16W	1 (14.30%)	0 (0%)	>0.9999
normal	2W, 4W, 16W	3 (42.85%)	6 (85.70%)	
soft	2W, 4W, 16W	3 (42.85%)	1 (14.30%)	
Expansion				
	time point post op	mean (±SD)	mean (±SD)	p value
Filling visits	6-8M	0.86 (±0.90)	0.86 (±0.90)	>0.9999

None of the expanders has shown any unexpected event (e.g., seroma, infection, wound dehiscence, malposition, or rotation) during these clinical controls. Likewise, the comparison of both devices showed no significant differences in palpation (Figure 3a) and the number of expander-filling visits for the full expansion of the devices (Figure 3b). Expander practicability and aesthetic outcome evaluation of devices by the surgeon reported a high satisfaction rating (scale of 10 - 7: very satisfied) for the lower pole expansion and footprint of both devices (Figure 3c).

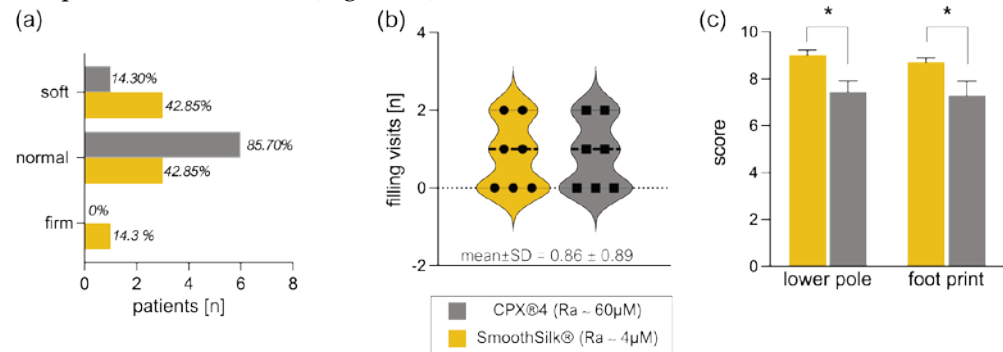


Figure 3. Intra-individual clinical evaluation of tissue expander performance after bilateral tissue expander-based breast reconstruction. Each patient received both types of expanders, the routinely used CPX@4 breast expanders (MENTOR®, USA: surface roughness: ~ 60 μM Ra) and the novel surface-roughness reduced SmoothSilk® breast expanders (Motiva Flora®, Establishment Labs, Costa Rica: surface roughness: ~ 4 μM Ra) randomized to the left or right breast after bilateral prophylactic NSME. **(a)** Evaluation of expander palpation 2W, 4W, and 16 W post-op. **(b)** Number of filling visits performed to full expansion of the device. **(c)** Surgeon satisfaction rating of tissue expander practicability 6-8 months post-op (lower pole: $p^*=0.023$, footprint: $p^*=0.043$; $n=7$). Mean values \pm SD of seven biological replicates (patients) are shown. The level for statistical significance was set at $p_{ns} > 0.05$, $p^* < 0.05$, $p^{**} < 0.002$, $p^{***} < 0.0002$, and $p^{****} < 0.0001$, for all statistical tests. (inter- and intra-individual comparison; $n=7$)

Strikingly, the standardized questionnaire revealed a significantly higher surgeon rating of satisfaction with both, the lower pole expansion (mean \pm SD = 9.0 ± 0.6) and overall footprint (mean \pm SD = 8.7 ± 0.5) of SmoothSilk® breast expanders (Figure 3d, Table 6) compared to the rougher CPX@4 device (lower pole: mean \pm SD = 7.4 ± 1.3 ; footprint: mean \pm SD = 7.3 ± 1.6).

Table 6. Satisfaction questionnaire – Surgeon and patient scale of device aesthetic, practicability, and comfortability outcome satisfaction.

	surface roughness	SmoothSilk® Ra ~ 4 μM		MentorCPX®4 Ra ~ 60 μM		p^{adj} value
		mean	\pm SD	mean	\pm SD	
Surgeon scale	time point post op	mean	\pm SD	mean	\pm SD	p^{adj} value
How satisfied are you with the lower pole expansion of the expander?	6-8 months	9.00	0.63	7.33	1.37	0.021872 *
How satisfied are you with the footprint created by the expander?	6-8 months	8.67	0.52	7.17	1.72	0.068264
Patient scale	time point post op	mean	\pm SD	mean	\pm SD	p^{adj} value
How satisfied are you with the expander?	4 weeks	9.50	1.22	7.67	1.21	0.026164*
Please indicate how comfortable the expander was?	6-8 months	8.83	0.98	5.67	2.88	0.028731*
Numeric scale	very satisfied : 10 to 7	satisfied: 7 to 4		not satisfied : 3 to 0		
	very comfortable: 10 to 7	comfortable: 7 to 4		not comfortable : 3 to 0		

3.3. Patient-reported aesthetic and comfort outcome after expander reconstruction

During regular clinical examinations, all included patients in this study completed two standardized questionnaires addressing patient satisfaction and comfortability with the expanders (Table 6), 4 weeks and 6-8 months post-op. The patients' rating of overall satisfaction with the expanders 4 weeks after implantation indicated a mean value of 9.57 (± 1.13) for the SmoothSilk® breast expander and 7.86 (± 1.22) for the rougher CPX®4 device. Although patients report generally high satisfaction with the aesthetic outcome of both devices 4 W post-op, patients presented more complaints about the comfortability (breast pain, breast discomfort, nipple sensitivity, and soreness) of CPX®4.

Surprisingly, the rating of expander comfortability after total expansion time, right before the exchange to definite implants, indicated a mean value of 8.85 (± 0.90) for the SmoothSilk® breast expander and 6.00 (± 2.77) for the rougher CPX®4 device. Hence, both patient-reported aesthetic and comfort outcome were significantly higher rated for the SmoothSilk® breast expander (Figure 4; satisfaction after 4W: $p^*=0.036$; comfortability after 6-8M: $p^*=0.036$).

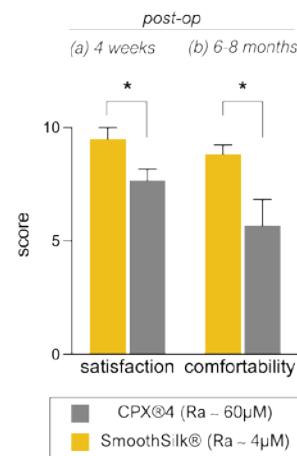


Figure 4. Patient (a) satisfaction and (b) comfortability rating of tissue expanders 4 weeks (a) and 6-8 months (b) post-op (satisfaction: $p^*=0.036$; comfortability: $p^*=0.036$; $n=7$). Mean values \pm SD of seven biological replicates (patients) are shown. The level for statistical significance was set at $p_{ns} > 0.05$, $p^* < 0.05$, $p^{**} < 0.002$, $p^{***} < 0.0002$, and $p^{****} < 0.0001$, for all statistical tests. (inter- and intra-individual comparison; $n=7$).

3.4. Cosmetic results

Evaluation of the aesthetic outcome was conducted by a four-member panel of plastic surgeons based on standardized photo documentation using the Breast Aesthetic Scale [66]. Intraindividual evaluation of the overall appearance showed a mean of 4.04 points for both devices and therefore did not reveal significant differences after the first stage of reconstruction (Table 7). Likewise, there was no significant difference between both expander types for all other aspects of breast aesthetics, details are given in Table 7. Evaluation of the second stage of reconstruction showed a trend towards a higher rating of the overall appearance compared to the first stage of reconstruction for both devices, but this was not found to be significant ($p=0.3803$ in Mentor CPX®4 breasts and $p=0.6370$ in SmoothSilk® breasts).

Table 7. Aesthetic evaluation of Mentor CPX®4 and SmoothSilk® expander devices after the first and second stages of reconstruction.

surface roughness	First stage of reconstruction					Second stage of reconstruction				
	Mentor CPX4*		SmoothSilk®*		p value	Mentor CPX4*		SmoothSilk®*		p value
	mean	± SD	mean	± SD		mean	± SD	mean	± SD	
Questions										
Breast										
Breast position	4.04	0.57	4.07	0.59	0.9173	4.25	0.50	4.25	0.58	> 0.9999
Inframammary fold	4.50	0.44	4.21	0.56	0.3454	4.38	0.49	4.50	0.48	0.6933
Volume	4.36	0.35	4.36	0.35	> 0.9999	4.38	0.66	4.29	0.68	0.8482
Shape and contour	3.79	0.85	3.75	0.81	0.9419	4.29	0.53	4.17	0.61	0.7355
Scar										
Appearance	4.54	0.47	4.46	0.59	0.8205	4.50	0.52	4.54	0.44	0.8943
Nipple-Areola Complex										
Nipple position	4.29	0.51	4.29	0.63	> 0.9999	4.58	0.47	4.29	0.73	0.4693
Overall Appearance	4.04	0.57	4.04	0.71	> 0.9999	4.38	0.66	4.25	0.75	0.7850

* Device used during 1st stage of reconstruction.

Evaluation of both reconstructive stages showed a trend towards a better rating for the questions symmetry, breast position, shape and contour, nipple position, and overall appearance after the second stage, as shown in Table 8. The highest increase was seen in the category shape and contour with a mean of 3.77 (\pm 0.83) points after the expander reconstruction compared to 4.23 (\pm 0.57) after the exchange for the final implant. Overall appearance increased from 4.04 (\pm 0.65) points to 4.31 (\pm 0.71) points after the second stage. The t-test did not prove the difference to be significant for all items. Results of the first and second reconstructive stages are shown in Table 8 and Figure 5.

Table 8. Aesthetic evaluation of cosmetic results after the first and the second stage of reconstruction.

Questions	first stage		second stage		p value
	mean	± SD	mean	± SD	
Breast					
Breast symmetry	4.29	0.54	4.42	0.49	0.6850
Breast position	4.05	0.58	4.25	0.54	0.4035
Inframammary fold	4.36	0.52	4.44	0.49	0.7031
Volume	4.36	0.35	4.33	0.67	0.9125
Shape and contour	3.77	0.83	4.23	0.57	0.1326
Scar					
Appearance	4.50	0.53	4.52	0.48	0.9216
Nipple-Areola Complex					
Nipple position	4.29	0.57	4.44	0.63	0.5428
Overall Appearance	4.04	0.65	4.31	0.71	0.3271

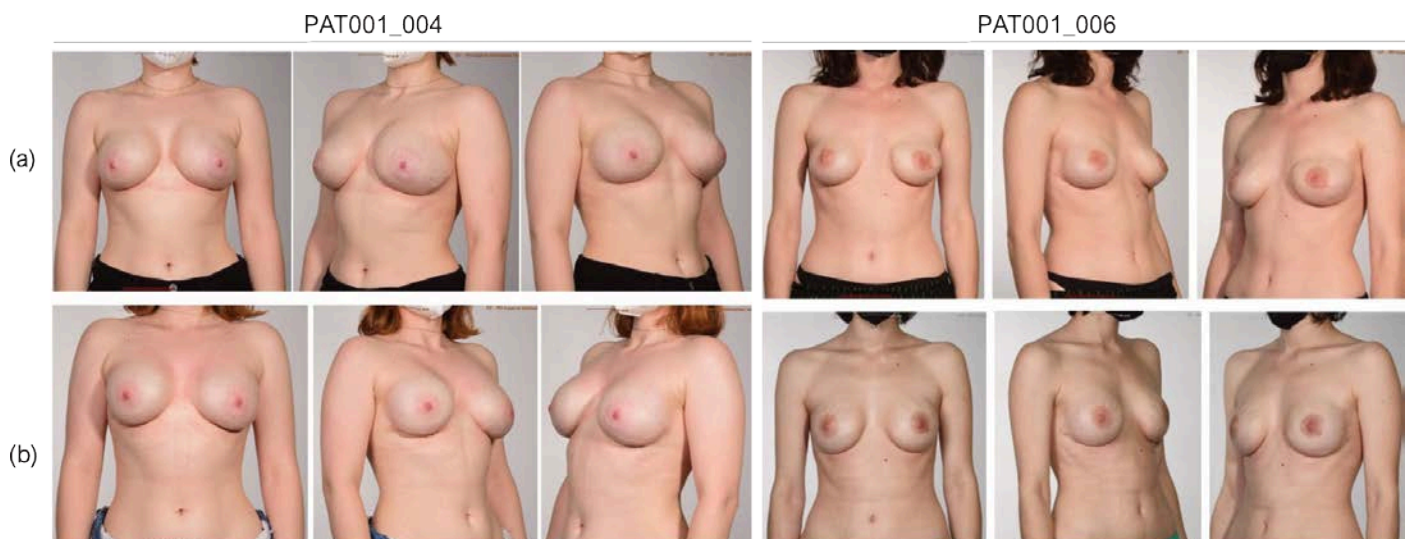

Figure 5. Photo documentation for cosmetic evaluation after the (a) first (PAT001_004 and PAT001_006; left breast: Mentor®CPX4, right breast: SmoothSilk®) and (b) second reconstructive stage (PAT001_004: Motiva Ergonomics SmoothSilk®, 450 cc, full projection, and PAT001_006: Motiva Ergonomics SmoothSilk®, 340 cc implants, demi).

3.5. Intra- and inter-individual comparison of the fibrotic capsule thickness formed around the CPX®4 and SmoothSilk® tissue expander

In all seven patients, the capsular tissue thickness was assessed by two different approaches, by non-invasive breast ultrasound, directly before-, and by histological analysis of peri-capsular tissue, harvested during re-operation, when expanders were exchanged for definitive implants.

Directly before the expander was exchanged, one single experienced radiologist (expert for breast ultrasound) determined capsular thickness, liquid accumulation, and signs of expander dislocation in a standardized o'clock position measurement (Figure 6a). An illustrative case of measurement position is shown in Figure 6b. Overall, ultrasound examination confirmed that the fibrotic capsule thickness on the rougher CPX®4 tissue expander was significantly thicker than the capsule formed on SmoothSilk® expanders (Figure 6c; $***p < 0.0001$) at 3 of the 4 positions assessed, however not at 12:00 o'clock at. Additionally, we detected exclusively in the 12 o'clock position, in the upper central part of the breast, periprosthetic fluid deposits around both expanders next to the port, with a significant increase around the rougher CPX®4 device (Figure 6d). However, expander identification, due to technical reasons (SmoothSilk®; integrated port), was not possible for the radiologist during the ultrasound assessment.

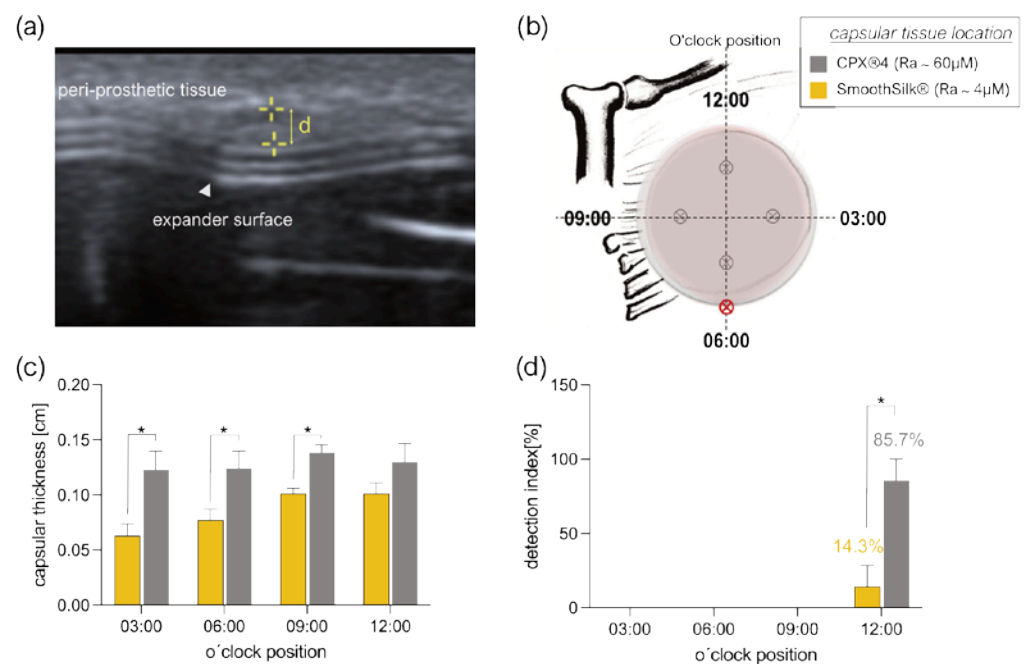


Figure 6. Ultrasonographic measurement of fibrotic peri-prosthetic capsule thickness of 7 patients was defined as the distance (a) from the silicon tissue expander surface to the outer margin of the capsule at the widest portion of the capsule and determined bilaterally at (b) o'clock reference positions 00:00, 03:00, 06:00, 09:00, 12:00 at of the left and right breast and. (c) Statistical significance was determined by 2-way ANOVA: O'clock position main effect: $F(3,24) = 1.615$, $p^{ns} = 0.2121$; expander surface roughness main effect: $F(1, 24) = 39.50$, $***p < 0.0001$; position \times expander roughness interaction effect: $F(3,24) = 0.9667$, $p^{ns} = 0.4246$. Multiple variance comparison within 4 measurement positions and post hoc Holm-Šidák p -value adjustment: 03:00, $***p_{adj} = 0.0008$; 06:00, $**p_{adj} = 0.0088$; 09:00, $*p_{adj} = 0.0490$; 12:00, $^{ns}p_{adj} = 0.1807$. (d) Detection of periprosthetic fluid deposits bilaterally at all 4 o'clock positions. Statistical significance was determined by 2-way ANOVA: O'clock position main effect: $F(3,48) = 24.50$, $***p < 0.0001$; expander surface roughness main effect: $F(1,48) = 12.50$, $***p = 0.0009$; position \times expander roughness interaction effect: $F(3,48) = 12.50$, $***p < 0.0001$. Multiple

variance comparison within 4 measurement positions and post hoc Holm-Šidák *p*-value adjustment: 03:00, ^{ns}*p*_{adj} < 0.9999; 06:00, ^{ns}*p*_{adj} < 0.9999; 09:00, ^{ns}*p*_{adj} < 0.9999; 12:00, ^{****}*p*_{adj} < 0.0001. Mean ± SEM of 7 patients in 7 independent experiments is shown. The level for statistical significance was set at *p*_{ns} > 0.05, *p** < 0.05, *p*** < 0.002, *p**** < 0.0002, and *p***** < 0.0001, for all statistical tests. (inter- and intra-individual comparison; n=7).

3.6. Titanium debris from TiLoop® Bra increases histopathological changes of the capsule

We studied 20 excised capsules in five patients, with samples collected (Figure 7a) anterior at the TiLOOP®/expander covered zone, and posterior at the expander/*M. pectoralis* contact zone in both breasts, around both tissue expanders. Comparison of fibrotic capsule thickness (Figure 7b) revealed not only a significantly thinner capsule around SmoothSilk® expanders with reduced surface roughness; Ra ~ 4 μM (Figure 7c; frontal contact zone: **p*=0.0361, distal zone ^{****}*p*<0.0001), but also a biologic effect of the Titan containing TiLOOP® pocket Bra, used for expander pocket fixation. The capsule was significantly thicker at the frontal TiLOOP®/expander contact zone around both expanders compared to the titan-free location at the distal *M. pectoralis* /expander contact zone (Figure 6c, CPX®4: ^{****}*p*<0.0001, SmoothSilk®: ^{****}*p*<0.0001).

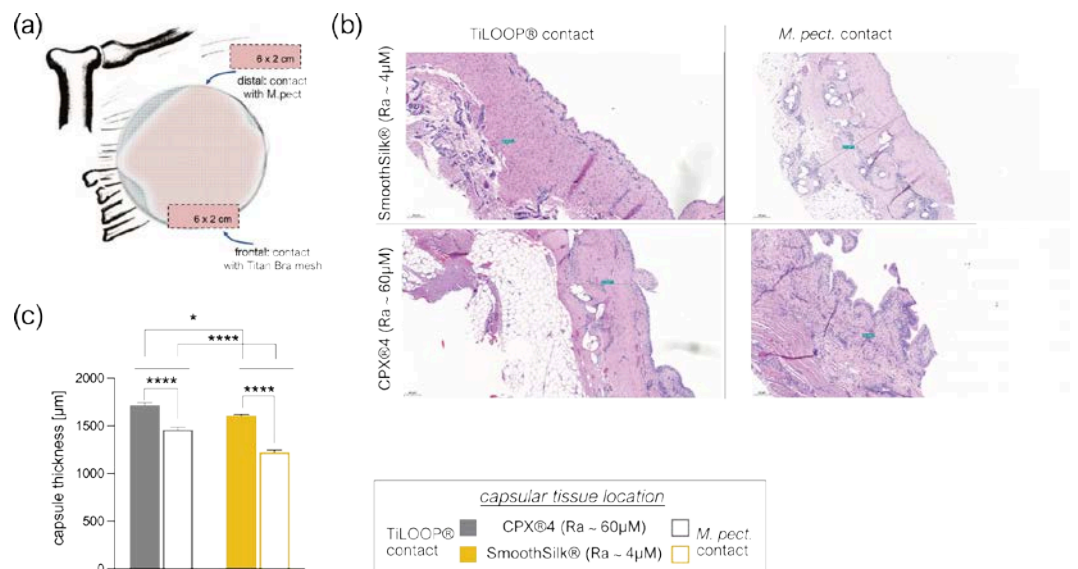


Figure 7. The thickness of the capsule formed around tissue expanders 6-8 months after bilateral tissue expander-based breast reconstruction. **(a)** Sample collection scheme for histological analysis of capsular thickness. **(b)** Hematoxylin and eosin stain of post-operative collected capsular tissue. **(c)** The thickness of the capsule of 7 patients was determined bilaterally in 2 biological replicates and 2 measurements per trial. Mean ± SEM of 7 patients in 7 independent experiments is shown. Statistical significance was determined by 2-way ANOVA: Capsular harvest position (contact zone) main effect: $F(1, 16) = 176.6$, ^{****}*p*<0.0001; expander surface roughness main effect: $F(1, 16) = 50.63$, ^{****}*p*<0.0001; harvest position × expander roughness interaction effect: $F(1, 16) = 7.026$, **p*=0.0174. The level for statistical significance was set at *p*_{ns} > 0.05, *p** < 0.05, *p*** < 0.002, *p**** < 0.0002, and *p***** < 0.0001, for all statistical tests. (inter- and intra-individual comparison; n=7).

4. Discussion

Despite clear evidence of superior long-term satisfaction after autologous breast reconstruction, the US, as well as Europe have experienced a clear shift towards implant-based breast reconstruction.

Silicone is the most widely used implant material in routine medical practice, despite side effects, such as the formation of hypertrophic fibrotic peri-implant capsules causing pain, local tissue damage, and impairment of implant function [67–70]. Surgical implantation of a biomaterial, no matter how noninvasive, causes injury that can initiate the fibrotic response [71, 72]. Any injury leads to inflammation, matrix formation, and matrix

rearrangement [31]. If the infection is associated with the biomaterial, the degree of fibrosis will increase dramatically [72].

Biomaterial surface chemistry, mechanical properties, and topography have been shown to influence the ultimate immune response [71, 73]. However, depending on the topography of these surfaces, varying degrees of capsular fibrosis are reported [46, 50, 74] as well as the finding that implants with an average roughness of $4\mu\text{m}$ provoke the least amount of inflammation and foreign body response [45]. Based on these histo-morphological analyses, a comparative evaluation of surface texture effect on implant encapsulation in patients and a controlled clinical setting is inevitable.

In this study, we intra- and inter-individually compared two commercial silicone breast tissue expanders with varied surface topographies: SmoothSilk® (Motiva; $R_a \sim 4\mu\text{M}$) and CPX®4 (Mentor $R_a \sim 60\mu\text{M}$) in a prophylactic setting. All patients received both devices, randomized to the left or right breast to define the consequences of SMI surface topography on specific outcomes: postoperative complications, implant rippling or malposition, and the aesthetic outcome.

In the course of intraindividual device performance comparison, no matching of patient groups was done. As both devices were inserted into every subject, no significant differences in patient characteristics, mastectomy weight, implant position (prepectoral), reconstruction volume and intraoperative filling or time point of expander exchange within comparative groups (SmoothSilk® vs CPX®4) could be determined. Weight of both mastectomized breasts correlated not only bilaterally (right vs left), but also in a simple regression with BMI, intermediate expansion volume of expanders, and final reconstruction volume of implants. The intermediate expansion volume and final implant reconstruction volume correlated bilaterally with each other and with BMI.

Concerning the BMI, all enrolled subjects could be discriminated as either normal weight ($18.5 - 24.9\text{ kg/m}^2$; $n=5$) or obese ($\text{BMI} > 30$; $n=2$). A $\text{BMI} > 30$ correspondingly also increased the weight of both breasts to $w^{\text{mast}} > 500\text{g}$. While smaller breasts ($w^{\text{mast}} < 500\text{g}$) have been reconstructed according to their initial weight, mastectomized breasts with a weight higher than 500g were reconstructed with T form reduction, though the final implant reconstruction volume did not correlate regressively with the BMI.

For women undergoing risk-reducing mastectomy to prevent breast cancer, reconstruction can be challenging in those with larger breasts. Large implants can increase the risk of complication rates, implant rippling, and capsular contracture. Additional surgery may be needed to correct an over-endowment in implant size[75]. To improve long-term aesthetic outcome and correspond to patients' will, we reduced breast size during reconstructive surgery.

Shell surface roughness variation did not affect post-operative complications evaluated in follow-up clinical examinations 2, 4, and 16 weeks post-operatively. There was no difference in filling attempts, procedure, or volume (intra-individually). Moreover, wound status and symmetry were comparable for both devices. Of note, in a recently published short-term prospective study, SmoothSilk® has shown a low rate of overall complications to date [76].

Crucially, in our study clinical and visual evaluation of tissue expander performance and practicability, by the surgeon, revealed significant benefits of the SmoothSilk® device. Not only, with improved palpation, as it was perceived as softer compared to CPX®4, but also in lower pole expansion creating an ideal footprint of the breast.

Importantly, patients shared the surgeon's practicability rating, very early after reconstruction (4W) and perceive the SmoothSilk® expander as significantly more comfortable compared to CPX®4. The correlation between surgeon and patient satisfaction reports is worth mentioning, as Wu and colleagues recently showed the striking effect of socioemotional determinants on patient and observer perception discrepancies in the assessment of aesthetic outcomes [77]. This might be due to technical differences of the expanders, as the filling port of CPX®4 is supported with magnetic metal inclusions, making it stiff and possibly irritating that position internally.

Aesthetic evaluation of both devices used for the first stage of reconstruction did not reveal significant differences. Likewise, cosmetic results were comparable after the second stage of reconstruction. Nevertheless, the impact of the type of expander on long-term results must be considered, since the formation of the capsule around the device takes place during the expansion period. Therefore, a permanent tissue footprint may influence the reconstructive results beyond this period. This may be regarded in the context of our radiological findings, where periprosthetic fluid and fibrotic capsule thickness were significantly increased around Mentor®CPX4 expanders. Furthermore, this is also strongly confirmed with the conducted histological analysis where the capsule tissue around SmoothSilk® expander devices was found to be significantly thinner. We hypothesize that these findings may give a hint about the inflammatory processes in the surrounding tissue and therefore may be linked to long-term complications such as capsular contracture or late seroma. In this study, mean follow-up was 36 days after device exchange, therefore no conclusions about long-term results can be drawn. This represents a limitation of our study, but we aim to conduct a sequel study evaluating the long-term results of our patients.

Our data suggest a trend towards better cosmetic results after the second stage of reconstruction, although this was not significant. Buck et al. revealed a significant improvement in cosmesis scores after the evaluation of different stages of reconstruction in their study [78]. We think that information about changes throughout the reconstructive period and the importance of completion must be part of the initial patient counseling to keep up patience for the final result and avoid rash frustration in patients. In our experience performance of the expander device is linked to the filling volume. We have observed that exhaustion of the expansion volume or even slight overfilling might lead to deformations, such as the prominence of the upper pole or even the rectangular shape of the expander (*Figure 5a*). Therefore, we prefer to stay under the maximum filling, but evaluation of these observations must be done in a further study.

Breast tissue expanders with magnetic ports, like CPX®4, are magnetic resonance imaging (MRI) unsafe, therefore non-invasive radiology is applied for diagnosing implant complications, implant displacement, or rotation. Ultrasound evaluation revealed significantly reduced capsules around SmoothSilk® expanders and a highly significant occurrence of seroma formation in the upper pole of the CPX® expander. The importance of this finding cannot be emphasized too much, as we suspect the stiffness of the magnetic filling port in CPX®4 is the cause of irritation and tissue disruption at that position internally. As already mentioned, the SmoothSilk® device does not only differ in surface topography but also in the nonmagnetic filling port with an incorporated radio frequency identification device to offer MRI scanning during the tissue expansion process[79]. Additionally, the SmoothSilk® expander might be through three fixation points identifiable by the radiologist during ultrasound assessment, thus permitting precise identification of the position through non-invasive, non-magnetic evaluation of displacement and rotation. Despite the clear benefits in terms of traceability, the absence of a stiff metallic region on the expander surface clearly reduces the foreign body response in form of capsular fibrosis around the SmoothSilk® device.

A variation in histomorphology was observed between samples. In general, the capsule region adjacent to the implant lacked vascularization, although vascularization throughout the entire capsule was evident in samples. After 6-8 months we found uncontracted capsules formed around both tissue expanders, composed of thin, loosely arranged, multidirectional, string-like fibers. Morphology consistent with synovial metaplasia was observed in some samples and was characterized by a layer of synovial-like cells arranged in a palisaded manner at the capsule-implant interface. Analysis of capsule thickness confirmed pre-operative ultrasound evaluation – tissue encapsulating SmoothSilk® expanders, is significantly thinner in comparison with CPX®4.

SMI design has been altered and improved over the years, including changes to the cohesiveness of the silicone filler gel and texturing of the shell. However, the basic device

design remains a silicone elastomer shell surrounding a viscous silicone gel, and biocompatibility, as well as safety, have been a source of a long-standing controversy. It is not only important to consider the effects of the elastomer shell but also of the filler gel.

Our findings of intracapsular silicone droplet inclusion substantiate previous findings of breast implant bleeding and debris-associated pathogenicity [80–82] over time, SMI rupture can appear by tears that occur in the implant shell, which often remain undetected. Virtually all SMI will bleed components from the filler gel, moreover, there is emerging evidence of severe biologic reactivity to breast implant particulate shedding [80]. Both, are associated with biological profibrotic hypersensitivity reactions and compromise the implant's long-term clinical performance.

Moreover, our data clearly reveal a TiLOOP® Bra Pocket conditioned increase in capsule thickness generally. Titanium-coated polypropylene meshes are a helpful device in breast surgery, where the prepectoral use of tissue bridging materials is indicated to fix the *Pectoralis major* and secure the position of SMI. However, these meshes have shown a variety of complication rates [83, 84]. Recently, Titan mesh incorporation in breast soft tissue after reconstruction was verified [85].

Up to this point, our clinical, radiological and histological impression is that the SmoothSilk® tissue expander with reduced surface roughness reduces fibrotic capsule formation and accumulation of periprosthetic fluid. Clinically, the improved biocompatibility is reflected in an improved aesthetic, practicability, and patient comfort outcome.

From a clinical point of view, capsular contracture, the most prominent complication associated with SMI, is defined by its symptoms, namely palpable hardness, visible deformities, or pain, of which the latter is an absolute indication for surgical intervention.

Therefore, evaluation of capsule thickness and its effects on implant performance (position, rotation) wound healing as well as patients' well-being is inevitable for the detection of clinical symptoms and therapeutic consequences. To sum up, reducing SMI shell surface roughness to Ra 4 μM can achieve an improved clinical and aesthetic outcome in breast reconstruction.

In general, SMI is designed to be nontoxic and non-immunogenic while keeping an active role in host response, which – we know - plays an active role in fibrogenesis. There is evidence to suggest, that biomechanical parameters, such as tensile strength, elasticity, and permeability of both tested devices should be carefully long-term evaluated as permeable gel leakage and particulate shedding through the outer shell cause serious health damage. By the same token, the fixation of breast implants with titanised, lightweight polypropylene meshes needs to be reevaluated in terms of biocompatibility.

5. Conclusions

First time investigated in patients, our data confirm an improved immune biocompatibility of a reduced implant surface topography in humans - with minor capsule formation, which leads long-term to lower revision rates and a better aesthetic outcome accompanied by higher patient satisfaction.

Author Contributions: D.W. and I.S. conceived the project and designed the experiments. D.E. and C.B. performed the NSME and D.W. performed tissue-expander-based breast reconstruction. B.A. performed all ultrasound evaluations. D.W. performed clinical examinations as well as questionnaires addressing aesthetics, practicability, and comfortability. D.W. and I.S. performed all sample collection experiments together. I.S. prepared the samples for histological analysis. B.Z. and A.B. performed all histology experiments. A.A. conceived and performed the cosmetic evaluation of outcomes and analyzed the data. I.S. analyzed patient characteristics, clinical examination, questionnaires, ultrasound, and histopathological data and is responsible for data curation. I.S. and A.A. wrote the manuscript and performed original draft preparation. D.W. reviewed and edited the original manuscript draft. I.S. visualized all data. I.S. was responsible for project administration. D.W. acquired funding for the project, supervised the clinical trial, and was responsible for the acquisition of the participants' informed consent.

Funding: Research on this project was funded by Establishment Labs, Costa Rica (ID D152500-015-015) to D.W.

Institutional Review Board Statement: The study was conducted in accordance with the Declaration of Helsinki, and approved by the Institutional Ethics Committee of the Medical University of Innsbruck (protocol code 1325/2019, approved on 23rd January 2020) and the Austrian Federal Office for Safety in Health Care (approval number; 13340962).

Informed Consent Statement: Informed consent was obtained from all subjects involved in the study.

Data Availability Statement: The data presented in this study are available on request from the corresponding author.

Acknowledgments: We thank Christian Ploner (Department for Plastic Surgery, Medical University of Innsbruck) for providing laboratory capacities as well as technical help; Selina Winkelmann and Monika Lahnthaler for assistance during surgeries and monitoring of appropriate collection of wound bed fluid; Karin Langert and Angelika Feichter for photo documentation of all our patients and Stephan Sigl, Petra Pülzl, Riccardo Lorenzini and Selina Winkelmann for cosmetic evaluation of the surgical results.

Conflicts of Interest: The authors declare no conflict of interest. The funders had no role in the design of the study; in the collection, analyses, or interpretation of data; in the writing of the manuscript; or in the decision to publish the results.

References

1. Plastic Surgery Statistics | American Society of Plastic Surgeons. 2022. <https://www.plasticsurgery.org/news/plastic-surgery-statistics>. Accessed November 21.
2. Collett, David J., Hinne Rakhorst, Peter Lennox, Mark Magnusson, Rodney Cooter, and Anand K. Deva. 2019. Current Risk Estimate of Breast Implant-Associated Anaplastic Large Cell Lymphoma in Textured Breast Implants. *Plastic and reconstructive surgery* 143. NLM (Medline): 30S-40S. <https://doi.org/10.1097/PRS.0000000000005567>.
3. Ferlay, Jacques, Isabelle Soerjomataram, Rajesh Dikshit, Sultan Eser, Colin Mathers, Marise Rebelo, Donald Maxwell Parkin, David Forman, and Freddie Bray. 2015. Cancer incidence and mortality worldwide: Sources, methods and major patterns in GLOBOCAN 2012. *International Journal of Cancer* 136. John Wiley & Sons, Ltd: E359–E386. <https://doi.org/10.1002/IJC.29210>.
4. OECD.stat. 2022. *Health Care Utilisation: Surgical procedures*. <https://stats.oecd.org>. Accessed November 7.
5. Fanakidou, Ioanna, Sofia Zyga, Victoria Alikari, Maria Tsironi, John Stathoulis, and Paraskevi Theofilou. 2018. Mental health, loneliness, and illness perception outcomes in quality of life among young breast cancer patients after mastectomy: the role of breast reconstruction. *Quality of Life Research* 27. Springer International Publishing: 539–543. <https://doi.org/10.1007/s11136-017-1735-x>.
6. Fortunato, Lucio, Andrea Loreti, Giuliana Cortese, Diana Spallone, Vito Toto, Francesco Cavaliere, Massimo Farina, et al. 2021. Regret and Quality of Life After Mastectomy With or Without Reconstruction. *Clinical Breast Cancer* 21. Elsevier Inc.: 162–169. <https://doi.org/10.1016/j.clbc.2019.11.005>.
7. Panchal, Hina, and Evan Matros. 2017. Current Trends in Postmastectomy Breast Reconstruction. *Plastic and reconstructive surgery* 140. *Plast Reconstr Surg*: 7S-13S. <https://doi.org/10.1097/PRS.0000000000003941>.
8. Santosa, Katherine B., Ji Qi, Hyungjin M. Kim, Jennifer B. Hamill, Edwin G. Wilkins, and Andrea L. Pusic. 2018. Long-term Patient-Reported Outcomes in Postmastectomy Breast Reconstruction. *JAMA Surgery* 153. American Medical Association: 891. <https://doi.org/10.1001/jamasurg.2018.1677>.
9. Toyserkani, Navid Mohamadpour, Mads Gustaf Jørgensen, Siavosh Tabatabaeifar, Tine Damsgaard, and Jens Ahm Sørensen. 2020. Autologous versus implant-based breast reconstruction: A systematic review and meta-analysis of Breast-Q patient-reported outcomes. *Journal of Plastic, Reconstructive and Aesthetic Surgery* 73. Elsevier Ltd: 278–285. <https://doi.org/10.1016/j.bjps.2019.09.040>.
10. Miseré, Renée ML, Sander MJ van Kuijk, Eva L. Claassens, Esther M. Heuts, Andrzej A. Piatkowski, and René RWJ van der Hulst. 2021. Breast-related and body-related quality of life following autologous breast reconstruction is superior to implant-based breast reconstruction - A long-term follow-up study. *Breast* 59: 176–182. <https://doi.org/10.1016/j.breast.2021.07.003>.
11. Lemaine, Valerie, Stephanie R Schilz, Holly K Van Houten, Lin Zhu, Elizabeth B Habermann, and Judy C Boughey. 2020. Autologous Breast Reconstruction versus Implant-Based Reconstruction: How Do Long-Term Costs and Health Care Use Compare? *Plastic and reconstructive surgery* 145. United States: 303–311. <https://doi.org/10.1097/PRS.0000000000006422>.
12. American Society Of Plastic Surgeons. 2022. *Plastic Surgery Statistics Report 2020: National Clearinghouse of Plastic Surgery Procedural Statistics*. <https://www.plasticsurgery.org/>. Accessed November 7.
13. Eriksen, Catharina, Emelie Nordstrand Lindgren, Jan Frisell, and Birgit Stark. 2012. A Prospective Randomized Study Comparing Two Different Expander Approaches in Implant-Based Breast Reconstruction. *Plastic & Reconstructive Surgery* 130: 254e–264e. <https://doi.org/10.1097/PRS.0b013e3182589ba6>.

14. Lee, Kyeong Tae, and Goo Hyun Mun. 2016. Comparison of one-stage vs two-stage prosthesis-based breast reconstruction: a systematic review and meta-analysis. *American Journal of Surgery* 212. Elsevier Inc: 336–344. <https://doi.org/10.1016/j.amjsurg.2015.07.015>.
15. Nahabedian, Maurice Y., and Steven R. Jacobson. 2019. Two-stage prepectoral breast reconstruction. *Gland Surgery*. AME Publishing Company. <https://doi.org/10.21037/gs.2018.09.04>.
16. Taylor, R. B., D. E. Eldred, G. Kim, J. M. Curtis, H. J. Brandon, and P. C. Klykken. 2008. Assessment of silicone gel breast implant biodurability by NMR and EDS techniques. *Journal of Biomedical Materials Research - Part A* 85. <https://doi.org/10.1002/jbm.a.31589>.
17. Stevens, W. Grant, Salvatore J. Pacella, Andrew J.L. Gear, Mark E. Freeman, Celeste McWhorter, Marissa J. Tenenbaum, and David A. Stoker. 2008. Clinical Experience With a Fourth-Generation Textured Silicone Gel Breast Implant: A Review of 1012 Mentor MemoryGel Breast Implants. *Aesthetic Surgery Journal* 28. <https://doi.org/10.1016/j.asj.2008.09.008>.
18. Bengtson, Bradley P., and Felmont F. Eaves. 2012. High-resolution ultrasound in the detection of silicone gel breast implant shell failure: Background, in vitro studies, and early clinical results. *Aesthetic Surgery Journal* 32. <https://doi.org/10.1177/1090820X11434507>.
19. Cole, Norman M. 2018. Consequences of the U.S. Food and Drug Administration-Directed Moratorium on Silicone Gel Breast Implants: 1992 to 2006. *Plastic and Reconstructive Surgery* 141. <https://doi.org/10.1097/PRS.00000000000004284>.
20. Cohen, Benjamin E., Thomas M. Biggs, Ernest D. Cronin, and Donald R. Collins. 1997. Assessment and longevity of the silicone gel breast implant. *Plastic and Reconstructive Surgery* 99. <https://doi.org/10.1097/00006534-199705010-00019>.
21. Lam, Martin C., Gisela Walgenbach-Brünagel, Alexey Pryalukhin, Jens Vorhold, Thomas Pech, Jörg C. Kalff, Glen Kristiansen, and Klaus J. Walgenbach. 2019. Management of Capsular Contracture in Cases of Silicone Gel Breast Implant Rupture with Use of Pulse Lavage and Open Capsulotomy. *Aesthetic Plastic Surgery* 43. <https://doi.org/10.1007/s00266-019-01463-w>.
22. Jasanof, Sheila. 2019. Expert games in silicone gel breast implant litigation. In *Science in Court*. <https://doi.org/10.4324/9780429436772-5>.
23. Henning, Chace, James Wang, Regina Swift, Benjamin Eades, Tanya M. Spektor, and James R. Berenson. 2020. Removal of a Silicone Gel Breast Implant in a Multiple Myeloma Patient Improved Disease Status: A Case Report. *Case Reports in Oncology*. <https://doi.org/10.1159/000508494>.
24. Glazebrook, Katrina N., Stefan Doerge, Shuai Leng, Tammy A. Drees, Katie N. Hunt, Shannon N. Zingula, Sandhya Pruthi, et al. 2019. Ability of dual-energy CT to detect silicone gel breast implant rupture and nodal silicone spread. *American Journal of Roentgenology* 212. <https://doi.org/10.2214/AJR.18.20138>.
25. Brown, S. L., G. Pennello, W. A. Berg, M. S. Soo, and M. S. Middleton. 2001. Silicone gel breast implant rupture, extracapsular silicone, and health status in a population of women. *Journal of Rheumatology* 28.
26. Alfano, Carmine, Marco Mazzocchi, and Nicolò Scuderi. 2004. Mammary compliance: An objective measurement of capsular contracture. *Aesthetic Plastic Surgery* 28. <https://doi.org/10.1007/s00266-004-4005-6>.
27. Henriksen, Trine F., Jon P. Fryzek, Lisbet R. Hölmich, Joseph K. McLaughlin, Kim Kjølner, Annette Pernille Høyer, Jørgen H. Olsen, and Søren Friis. 2005. Surgical intervention and capsular contracture after breast augmentation: A prospective study of risk factors. *Annals of Plastic Surgery* 54. <https://doi.org/10.1097/01.sap.0000151459.07978.fa>.
28. Brody, G. S. 1997. On the safety of breast implants. *Plastic and Reconstructive Surgery*. <https://doi.org/10.1097/00006534-199710000-00039>.
29. Henriksen, Trine F., Lisbet R. Hölmich, Jon P. Fryzek, Søren Friis, Joseph K. McLaughlin, Annette Pernille Høyer, Kim Kjølner, and Jørgen H. Olsen. 2003. Incidence and Severity of Short-Term Complications after Breast Augmentation: Results from a Nationwide Breast Implant Registry. *Annals of Plastic Surgery* 51. <https://doi.org/10.1097/01.sap.0000096446.44082.60>.
30. Handel, Neal, Tracy Cordray, Jaime Gutierrez, and J. Arthur Jensen. 2006. A long-term study of outcomes, complications, and patient satisfaction with breast implants. *Plastic and Reconstructive Surgery* 117. *Plast Reconstr Surg*: 757–767. <https://doi.org/10.1097/01.prs.0000201457.00772.1d>.
31. Wick, Georg, Cecilia Grundtman, Christina Mayerl, Thomas-Florian Florian Wimpissinger, Johann Feichtinger, Bettina Zelger, Roswitha Sgonc, and Dolores Wolfram. 2013. *The immunology of fibrosis*. *Annual Review of Immunology*. Vol. 31. <https://doi.org/10.1146/annurev-immunol-032712-095937>.
32. Ji, Litong, Tie Wang, Lining Tian, Hongjiang Song, and Meizhuo Gao. 2020. Roxatidine inhibits fibrosis by inhibiting NF-κB and MAPK signaling in macrophages sensing breast implant surface materials. *Molecular Medicine Reports* 21. Spandidos Publications: 161–172. <https://doi.org/10.3892/mmr.2019.10815>.
33. Kuehlmann, Britta A., Clark Andrew Bonham, and Geoffrey C. Gurtner. 2019. Abstract 114. Targeting Wnt Signaling to Reduce Capsular Fibrosis. *Plastic and Reconstructive Surgery - Global Open* 7. Ovid Technologies (Wolters Kluwer Health): 80. <https://doi.org/10.1097/01.gox.0000558388.69103.8d>.
34. Kuo, Yao Lung, I. Ming Jou, Seng Feng Jeng, Chun Hui Chu, Jhy Shrian Huang, Tai I. Hsu, Li Ren Chang, Po Wei Huang, Jian An Chen, and Ting Mao Chou. 2019. Hypoxia-induced epithelial-mesenchymal transition and fibrosis for the development of breast capsular contracture. *Scientific Reports* 9. Nature Publishing Group: 1–6. <https://doi.org/10.1038/s41598-019-46439-7>.
35. Biernacka, Anna, Marcin Dobaczewski, and Nikolaos G. Frangogiannis. 2011. TGF-β signaling in fibrosis. *Growth Factors* 29: 196–202. <https://doi.org/10.3109/08977194.2011.595714>.
36. Chaikuad, Apirat, and Alex N. Bullock. 2016. Structural basis of intracellular TGF-β signaling: Receptors and smads. *Cold Spring Harbor Perspectives in Biology* 8. Cold Spring Harbor Laboratory Press. <https://doi.org/10.1101/cshperspect.a022111>.

37. Meng, Xiao Ming, David J. Nikolic-Paterson, and Hui Yao Lan. 2016. TGF- β : The master regulator of fibrosis. *Nature Reviews Nephrology*. Nature Publishing Group. <https://doi.org/10.1038/nrneph.2016.48>.
38. Lan, Hui Yao. 2011. Diverse roles of TGF- β /Smads in renal fibrosis and inflammation. *International Journal of Biological Sciences*. Ivyspring International Publisher. <https://doi.org/10.7150/ijbs.7.1056>.
39. Margadant, Coert, and Arnoud Sonnenberg. 2010. Integrin-TGF-B crosstalk in fibrosis, cancer and wound healing. *EMBO Reports*. <https://doi.org/10.1038/embor.2009.276>.
40. Hu, He He, Dan Qian Chen, Yan Ni Wang, Ya Long Feng, Gang Cao, Nosratola D. Vaziri, and Ying Yong Zhao. 2018. New insights into TGF- β /Smad signaling in tissue fibrosis. *Chemico-Biological Interactions*. Elsevier Ireland Ltd. <https://doi.org/10.1016/j.cbi.2018.07.008>.
41. ISO - ISO 14607:2018 - Non-active surgical implants – Mammary implants – Particular requirements. 2022. <https://www.iso.org/standard/63973.html>. Accessed November 17.
42. Stevens, W. Grant, Maurice Y. Nahabedian, M. Bradley Calobrace, Jennifer L. Harrington, Peter J. Capizzi, Robert Cohen, Rosalyn C. D'incelli, and Maggi Beckstrand. 2013. Risk factor analysis for capsular contracture: A 5-year sientra study analysis using round, smooth, and textured implants for breast augmentation. *Plastic and Reconstructive Surgery*. <https://doi.org/10.1097/01.prs.0000435317.76381.68>.
43. Webb, Leland H., Victoria L. Aime, Annie Do, Kenneth Mossman, and Raman C. Mahabir. 2017. Textured breast implants: A closer look at the surface debris under the microscope. *Plastic Surgery* 25. <https://doi.org/10.1177/2292550317716127>.
44. Martin, erna v., Weiguang Ho, and Khalid Khan. 2019. An extended 7-year review of textured breast implants for primary breast augmentation: Allergan® versus Mentor®. *Annals of Breast Surgery* 3. <https://doi.org/10.21037/abs.2019.06.01>.
45. Doloff, Joshua C., Omid Veisesh, Roberto de Mezerville, Marcos Sforza, Tracy Ann Perry, Jennifer Haupt, Morgan Jamiel, et al. 2021. The surface topography of silicone breast implants mediates the foreign body response in mice, rabbits and humans. *Nature Biomedical Engineering* 2021 5:10 5. Nature Publishing Group: 1115–1130. <https://doi.org/10.1038/s41551-021-00739-4>.
46. Cappellano, Giuseppe, Christian Ploner, Susanne Lobenwein, Sieghart Sopper, Paul Hoerthnagl, Christina Mayerl, Nikolaus Wick, Gerhard Pierer, Georg Wick, and Dolores Wolfram. 2018. Immunophenotypic characterization of human T cells after in vitro exposure to different silicone breast implant surfaces. *PLoS ONE*. <https://doi.org/10.1371/journal.pone.0192108>.
47. Lam, Mylan, Véronique Migonney, and Céline Falentin-Daudre. 2021. Review of silicone surface modification techniques and coatings for antibacterial/antimicrobial applications to improve breast implant surfaces. *Acta Biomaterialia*. Acta Materialia Inc. <https://doi.org/10.1016/j.actbio.2020.11.020>.
48. Atlan, Michael, Gina Nuti, Hongpeng Wang, Sherri Decker, and Tracy Ann Perry. 2018. Breast implant surface texture impacts host tissue response. *Journal of the Mechanical Behavior of Biomedical Materials* 88. Elsevier Ltd: 377–385. <https://doi.org/10.1016/j.jmbbm.2018.08.035>.
49. Cheng, Zhu, Carolyn R. Shurer, Samuel Schmidt, Vivek K. Gupta, Grace Chuang, Jin Su, Amanda R. Watkins, et al. 2020. The surface stress of biomedical silicones is a stimulant of cellular response. *Science Advances* 6. American Association for the Advancement of Science: 76–86. <https://doi.org/10.1126/sciadv.aay0076>.
50. Kyle, Daniel J.T., Antonios Oikonomou, Ernie Hill, and Ardeshir Bayat. 2015. Development and functional evaluation of biomimetic silicone surfaces with hierarchical micro/nano-topographical features demonstrates favourable invitro foreign body response of breast-derived fibroblasts. *Biomaterials* 52. Elsevier Ltd: 88–102. <https://doi.org/10.1016/j.biomaterials.2015.02.003>.
51. Atlan, Michael, Gina Nuti, Hongpeng Wang, Sherri Decker, and Tracy Ann Perry. 2018. Breast implant surface texture impacts host tissue response. *Journal of the Mechanical Behavior of Biomedical Materials* 88. Elsevier Ltd: 377–385. <https://doi.org/10.1016/j.jmbbm.2018.08.035>.
52. Valencia-Lazcano, Anai A., Teresa Alonso-Rasgado, and Ardeshir Bayat. 2013. Characterisation of breast implant surfaces and correlation with fibroblast adhesion. *Journal of the Mechanical Behavior of Biomedical Materials* 21. Elsevier: 133–148. <https://doi.org/10.1016/j.jmbbm.2013.02.005>.
53. McLaughlin, Caroline, Alexa J Hughes, Christopher S Parham, Madelaine Fritsche, John D Potochny, Allen Kunselman, and Dino J Ravnic. 2022. Smooth Versus Textured Tissue Expander Breast Reconstruction: Complications and Efficacy. *Annals of plastic surgery* 88. United States: S288–S292. <https://doi.org/10.1097/SAP.0000000000003193>.
54. Giot, Jean Philippe, Laurence S. Paek, Nathanael Nizard, Mostafa El-Diwany, Louis A. Gaboury, Monica Nelea, Joseph S. Bou-Merhi, Patrick G. Harris, and Michel A. Danino. 2015. The double capsules in macro-textured breast implants. *Biomaterials* 67. Elsevier Ltd: 65–72. <https://doi.org/10.1016/j.biomaterials.2015.06.010>.
55. Hall-Findlay, Elizabeth J. 2011. Breast implant complication review: Double capsules and late seromas. *Plastic and Reconstructive Surgery* 127: 56–66. <https://doi.org/10.1097/PRS.0b013e3181fad34d>.
56. Loch-Wilkinson, Anna, Kenneth J. Beath, Robert John William Knight, William Louis Fick Wessels, Mark Magnusson, Tim Papadopoulos, Tony Connell, et al. 2017. Breast implant-associated anaplastic large cell lymphoma in Australia and New Zealand: High-surface-area textured implants are associated with increased risk. *Plastic and Reconstructive Surgery* 140: 645–654. <https://doi.org/10.1097/PRS.0000000000003654>.
57. Hu, Honghua, Anita Jacombs, Karen Vickery, Steven L Merten, David G Pennington, and Anand K Deva. 2015. Chronic biofilm infection in breast implants is associated with an increased T-cell lymphocytic infiltrate: implications for breast implant-associated lymphoma. *Plastic and reconstructive surgery* 135. United States: 319–329. <https://doi.org/10.1097/PRS.0000000000000886>.
58. Loch-Wilkinson, Anna, Kenneth J. Beath, Robert John William Knight, William Louis Fick Wessels, Mark Magnusson, Tim Papadopoulos, Tony Connell, et al. 2017. Breast implant-associated anaplastic large cell lymphoma in Australia and New

- Zealand: High-surface-area textured implants are associated with increased risk. *Plastic and Reconstructive Surgery* 140. <https://doi.org/10.1097/PRS.0000000000003654>.
59. Zhang, Xin Rui, Pham Ngoc Chien, Xuan-Tung Trinh, Sun-Young Nam, and Chan-Yeong Heo. 2022. Comparison of Formation of Capsule Among Different Breast Silicone Implants. *In vivo (Athens, Greece)* 36. Greece: 2756–2766. <https://doi.org/10.21873/invivo.13012>.
60. Lee, Kyeong-Tae, Hae Yeon Park, Byung-Joon Jeon, Goo-Hyun Mun, Sa Ik Bang, and Jai Kyong Pyon. 2021. Does the Textured-Type Tissue Expander Affect the Outcomes of Two-Stage Prosthetic Breast Reconstruction? A Propensity Score Matching Analysis between Macrot textured and Microtextured Expanders. *Plastic & Reconstructive Surgery* 147. Lippincott Williams and Wilkins: 545–555. <https://doi.org/10.1097/PRS.0000000000007634>.
61. Fairchild, Berry, Warren Ellsworth, Jesse C Selber, P David, Dmitry Zavlin, Stephanie Nemir, M Cristina, and Mark W Clemens. 2020. Safety and Efficacy of Smooth Surface Tissue Expander Breast Reconstruction 40: 53–62. <https://doi.org/10.1093/asj/sjy199>.
62. Chiu, Wen-Kuan, Megan Fracol, Lauren N Feld, Cecil S Qiu, and John Y S Kim. 2021. Judging an Expander by Its Cover: A Propensity-Matched Analysis of the Impact of Tissue Expander Surface Texture on First-Stage Breast Reconstruction Outcomes. *Plastic and reconstructive surgery* 147. United States: 1e–6e. <https://doi.org/10.1097/PRS.0000000000007417>.
63. Wolfram, Dolores, Christian Rainer, Harald Niederegger, Hildegunde Piza, and Georg Wick. 2004. Cellular and molecular composition of fibrous capsules formed around silicone breast implants with special focus on local immune reactions *. *Journal of Autoimmunity* 23. Academic Press: 81–91. <https://doi.org/10.1016/j.jaut.2004.03.005>.
64. Wolfram, D., B. Oberreiter, C. Mayerl, E. Soelder, H. Ulmer, H. Piza-Katzer, G. Wick, and A. Backovic. 2008. Altered systemic serologic parameters in patients with silicone mammary implants. *Immunology Letters* 118. Immunol Lett: 96–100. <https://doi.org/10.1016/j.imlet.2008.03.007>.
65. Duraes, Eliana F. R., Paul Durand, Megan Morisada, Isis Scomacao, Leonardo C. Duraes, Joao Batista de Sousa, Nasim Abedi, et al. 2022. A Novel Validated Breast Aesthetic Scale. *Plastic & Reconstructive Surgery* 149. Ovid Technologies (Wolters Kluwer Health): 1297–1308. <https://doi.org/10.1097/prs.00000000000009156>.
66. Duraes, Eliana F. R., Paul Durand, Megan Morisada, Isis Scomacao, Leonardo C. Duraes, Joao Batista de Sousa, Nasim Abedi, et al. 2022. A Novel Validated Breast Aesthetic Scale. *Plastic and reconstructive surgery* 149. Plast Reconstr Surg: 1297–1308. <https://doi.org/10.1097/PRS.00000000000009156>.
67. Prantl, Lukas, Stephan Schreml, Stefan Fichtner-Feigl, Nina Pöpl, Marita Eisenmann-Klein, Hartmut Schwarze, and Bernd Füchtmeier. 2007. Clinical and morphological conditions in capsular contracture formed around silicone breast implants. *Plastic and reconstructive surgery* 120. Plast Reconstr Surg: 275–284. <https://doi.org/10.1097/01.PRS.0000264398.85652.9A>.
68. Siggelkow, Wulf, D. M. Gescher, A. Siggelkow, D. Klee, E. Malik, W. Rath, and A. Faridi. 2004. In vitro analysis of modified surfaces of silicone breast implants. *The International journal of artificial organs* 27. Int J Artif Organs: 1100–1108. <https://doi.org/10.1177/039139880402701214>.
69. Siggelkow, Wulf, Andre Faridi, Katrin Spiritus, Uwe Klinge, Werner Rath, and Bernd Klosterhalfen. 2003. Histological analysis of silicone breast implant capsules and correlation with capsular contracture. *Biomaterials* 24. Elsevier: 1101–1109. [https://doi.org/10.1016/S0142-9612\(02\)00429-5](https://doi.org/10.1016/S0142-9612(02)00429-5).
70. Handel, Niel, J. Arthur Jensen, Quieten Black, James R. Waisman, and Melvin J. Silverstein. 1995. The fate of breast implants: A critical analysis of complications and outcomes. *Plastic and Reconstructive Surgery* 96. Lippincott Williams and Wilkins: 1521–1533. <https://doi.org/10.1097/00006534-199512000-00003>.
71. Mempin, Maria, Honghua Hu, Durdana Chowdhury, Anand Deva, and Karen Vickery. 2018. The A, B and C's of silicone breast implants: Anaplastic large cell lymphoma, biofilm and capsular contracture. *Materials*. MDPI AG. <https://doi.org/10.3390/ma11122393>.
72. Bizjak, Mojca, Carlo Selmi, Sonja Praprotnik, Or Bruck, Carlo Perricone, Michael Ehrenfeld, and Yehuda Shoenfeld. 2015. Silicone implants and lymphoma: The role of inflammation. *Journal of Autoimmunity*. Academic Press. <https://doi.org/10.1016/j.jaut.2015.08.009>.
73. Zhang, Mengjuan, and Song Zhang. 2020. T Cells in Fibrosis and Fibrotic Diseases. *Frontiers in Immunology*. Frontiers Media S.A. <https://doi.org/10.3389/fimmu.2020.01142>.
74. Shin, Byung Ho, Byung Hwi Kim, Sujin Kim, Kangwon Lee, Young Bin Choy, and Chan Yeong Heo. 2018. Silicone breast implant modification review: Overcoming capsular contracture. *Biomaterials Research*. BioMed Central Ltd. <https://doi.org/10.1186/s40824-018-0147-5>.
75. Risks and Complications of Breast Implants | FDA. 2022. <https://www.fda.gov/medical-devices/breast-implants/risks-and-complications-breast-implants>. Accessed November 21.
76. Sforza, Marcos, Renato Zaccheddu, Angelo Alleruzzo, Adriano Seno, Domenico Mileto, Arnaldo Paganelli, Hassan Sulaiman, Michael Payne, and Lajos Maurovich-Horvat. 2018. Preliminary 3-Year Evaluation of Experience With SilkSurface and VelvetSurface Motiva Silicone Breast Implants: A Single-Center Experience With 5813 Consecutive Breast Augmentation Cases. *Aesthetic Surgery Journal* 38. Oxford University Press: S62. <https://doi.org/10.1093/ASJ/SJX150>.
77. Wu, Shannon S., Eliana F.R. Duraes, Isis Scomacao, Megan Morisada, Risal S. Djohan, Steven L. Bernard, Andrea Moreira, and Graham S. Schwarz. 2022. Beauty Is in the Eye of the Beholder: Factors Influencing Disparity in Perceptions of Breast Reconstruction Aesthetic Outcomes. *Plastic and reconstructive surgery* 150. Plast Reconstr Surg: 42E–50E. <https://doi.org/10.1097/PRS.00000000000009254>.

78. Buck, Donald W., Deana Shenaq, Kamaldeep Heyer, Caroline Kato, and John Y.S. Kim. 2010. Patient-subjective cosmetic outcomes following the varying stages of tissue expander breast reconstruction: The importance of completion. *The Breast* 19. Netherlands: 521–526. <https://doi.org/10.1016/j.breast.2010.05.017>.
79. Mendonça Munhoz, Alexandre, Luciano Chala, Giselle Guedes de Melo, Ary De Azevedo Marques Filho, Tatiana Tucunduva, and Rolf Gemperli. 2019. Usefulness of Radio Frequency Identification Device in Diagnosing Rotation of Motiva SmoothSilk Implants after Augmentation Mammoplasty. *Plastic and Reconstructive Surgery Global Open* 7. Wolters Kluwer Health. <https://doi.org/10.1097/GOX.0000000000002497>.
80. Hallab, Nadim James, Lauryn Samelko, and Dennis Hammond. 2019. The Inflammatory Effects of Breast Implant Particulate Shedding: Comparison With Orthopedic Implants. *Aesthetic Surgery Journal* 39. Oxford University Press: S36. <https://doi.org/10.1093/ASJ/SJY335>.
81. Kappel, Rita M, Antonius J H Klunder, and Ger J M Pruijn. 2022. Silicon chemistry and silicone breast implants. <https://doi.org/10.1007/s00238-013-0914-4>.
82. Implants, Institute of Medicine (US) Committee on the Safety of Silicone Breast, Stuart Bondurant, Virginia Ernster, and Roger Herdman. 1999. Immunology of Silicone. National Academies Press (US).
83. Dieterich, Max, Stefan Paepke, Karin Zwiefel, Holger Dieterich, Jens Blohmer, Andree Faridi, Evelyn Klein, Bernd Gerber, and Carolin Nestle-Kraemling. 2013. Implant-based breast reconstruction using a titanium-coated polypropylene mesh (TiLOOP Bra): a multicenter study of 231 cases. *Plastic and reconstructive surgery* 132. Plast Reconstr Surg. <https://doi.org/10.1097/PRS.0B013E318290F8A0>.
84. Chen, W. X., L. Cheng, L. Y. Xu, and Y. L. Zhu. 2019. A short follow-up of prosthesis-based breast reconstruction using TiLOOP® Bra surgical mesh. *Nigerian journal of clinical practice* 22. Niger J Clin Pract: 1115–1119. https://doi.org/10.4103/NJCP.NJCP_487_18.
85. Casella, Donato, Marco Bernini, Lapo Bencini, Jenny Roselli, Maria Teresa Lacaria, Jacopo Martellucci, Roberto Banfi, Claudio Calabrese, and Lorenzo Orzalesi. 2014. TiLoop® Bra mesh used for immediate breast reconstruction: comparison of retropectoral and subcutaneous implant placement in a prospective single-institution series. *European journal of plastic surgery* 37. Eur J Plast Surg: 599–604. <https://doi.org/10.1007/S00238-014-1001-1>.