

Review

Dental Wear: Attrition, Erosion and Abrasion—A Palaeo-Odontological Approach

Geoffrey H. Sperber

Faculty of Medicine & Dentistry, University of Alberta, Edmonton, AB T6G 2R3, Canada;
gsperber@ualberta.ca

Abstract: A review of the surface ablation of hominin teeth by attrition, abrasion and erosive wear. The occurrence of these lesions is explored in a sample of South African fossil australopithecine dentitions revealing excessive wear. Interpretation of the nature of the dietary components causing such wear in the absence of carious erosion provides insight into the ecology of the Plio-pleistocene epoch (1-2 million years ago). Fossil teeth inform much of the living past by their retained evidence after death. Tooth wear is the ultimate forensic evidence of lives lived.

Keywords: tooth wear; attrition; erosion; abrasion; palaeo-odontology

1. Introduction

The wear of teeth is an inevitable consequence of their evolutionary designated purpose of food acquisition by predation, apprehension, grasping, trituration, mastication and ingestion. The enormous variety of shapes, sizes and locations of teeth encountered in comparative odontology attests to the innovative evolutionary outcomes of obtaining sustenance for survival. The mechanism of odontogenesis whereby amelogenesis is completed by the demise of ameloblasts ensures that no repair mechanism exists for repair of worn or damaged enamel. Accordingly, any occurrence of damage of whatever source is permanently imprinted upon the hardest and most prolonged remains of creatures possessing teeth. The study of the impingement upon teeth by different elements constitutes the purpose of this investigation.

Dental attrition is caused by tooth to tooth contact forming acquired wear facets upon pristine enamel, whereas abrasion is caused by food and foreign body contact (e.g. tooth brushing) that may obliterate attrition wear patterns. Finally, erosion by acid-based leaching and dissolution of the hydroxyapatite crystals of enamel may override previous lesions of enamel. Accordingly, critical analysis of the causes and history of damaged enamel needs to be undertaken in identifying its initial origin. Tooth wear is thus multifactorial in origin, based upon diet and eating habits, oral hygiene, bruxism, brushing habits, xerostomia, anorexia, gastro-esophageal reflux disease (GERD), vomiting, bulimia as well as medications and dietary supplements. A need for standardization and classification of these multiple determinants of dental deterioration has been proposed (1). Dental surface texture analysis provides evidence of the etiological factors implicated in attrition and erosion (2).

2. Etiology of Dental Wear.

The phenomenon of dental wear is peculiarly allied to both clinical dentistry and to comparative odontology and palaeoanthropology. The patterns of wear upon teeth become at once both a clinical concern in current dental practice, of interest in forensic odontology and the subject of exploration in palaeodontology. The occlusal wear pattern created in ideal contemporary dentitions reveals an antero-posterior curvature of the mandibular teeth first described by Ferdinand Graf von Spee (4,5). By contrast, the curve of Wilson observed in the coronal plane is an upward U-shaped curvature of the maxillomandibular occlusal plane. These attritional wear planes are dependent upon the main masticatory forces exerted by the masseter and temporalis

muscles that provide the most favourable loading forces upon the teeth. Thus, attritional tooth wear must be considered a physiological phenomenon, creating the Monson curve of occlusion. This normal wear pattern must be contrasted with pathological abrasional wear caused by bruxism, jaw clenching, pipe-clenching, oral musical instrument usage, bottle- cap opening and use of teeth for gripping objects. Dental erosion is always pathological. expression.

Different categories of teeth wear at different rates. Thus, incisors suffer the greatest wear (97%), followed by the molars (85%), then the canines (74%), with the premolars the least worn (60-68%) (6).

3. Enamel Thickness

As enamel is the tissue most subject to wear, the hardness and thickness of enamel become evolutionary responses to ecological and dietary variations. Thus, the thickened enamel of Australopithecine dentitions contrasts sharply with the thin enamel of orang utans (*Pongo pygmaeus*), chimpanzees (*Pan troglodytes*) and Gorillas, reflecting their dietary habits. Much can be inferred from varying enamel thicknesses (7, 8).

Dental microwear patterns reveal both occlusal dynamics and the nature of the diets and the properties of the procured and ingested food. Scanning electron microscopy and stable isotopes can identify specific patterns of enamel wear related to particular diets or tooth use behavior (9). The characteristics of microwear provide implications for hominin diets (10).

Enamel structure by prismatic weaving limiting stress fracturing causes differential resistance to wear, effectively sculpting occlusal surfaces by variable abrasive patterns. Prism orientation in enamel can direct abrasion and attrition to form ridges or sharp edges for trituration efficiency.

The pattern of attritional wear plays a significant role in explicating the nature of dietary material. The palaeocology of extinct hominins can be elicited from dental microwear and isotopic analysis of enamel (11)). In this respect, the degree and wear patterns of fossil hominid dentitions are revealing of past ecological habitats. The folivorous diet of the great apes, relatively clean of abrasive grit, is not as wearing on dental enamel as the presumed gritty omnivorous diet (roots, sedges, meat and bones) of australopithecines and modern man. The selective dietary pressures for thicker enamel are evident in the greater longevity of hominids, including man, compared to the briefer lives of thin enameled pongids.

4. Australopithecine and Paranthropus Dentitions.

The australopithecines existed between three and two million years ago in various African fossil sites. The distinctions drawn between “gracile”(Australopithecus africanus) and “robust” australopithecines (Paranthropus robustus) are based not only on differences in gross morphology, but also on their dentitions (11, 12). The variation in dental microwear exhibited between these species leads to inconclusive determination of the dietary causative factors of their tooth wear patterns. Isotopic evidence of dental components further compounds the variability of dietary intake (13).

The following Australopithecine dentitions exhibit varying degrees of attritional and abrasion wear. The images portrayed are from original photographs and X-rays taken in 1970-1972 at the University of the Witwatersrand, Johannesburg, South Africa as part of a PhD thesis (14).

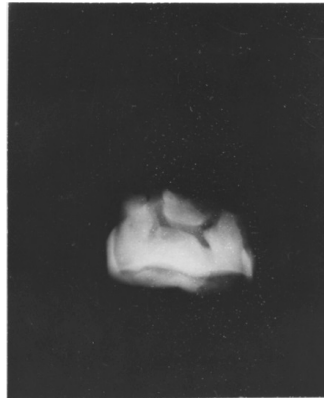

Fig.1. *Australopithecus africanus*. StW Hom 1/68. Radiograph of isolated maxillary M1 crown. The buccal and lingual edges of the worn occlusal surface are seen as wavy lines reflecting the scalloped occlusal table. The severe wear impacted the underlying dentine, resulting in a secondary dentine deposition in the pulp chamber. The roots of this specimen were broken off.

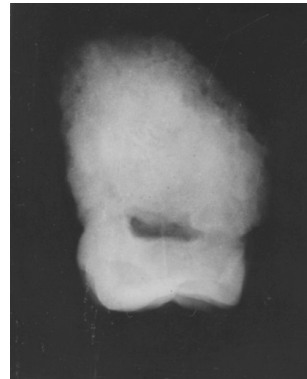

Fig.2. *Australopithecus africanus* StW Hom 2/69. Radiograph of isolated maxillary M3 crown.

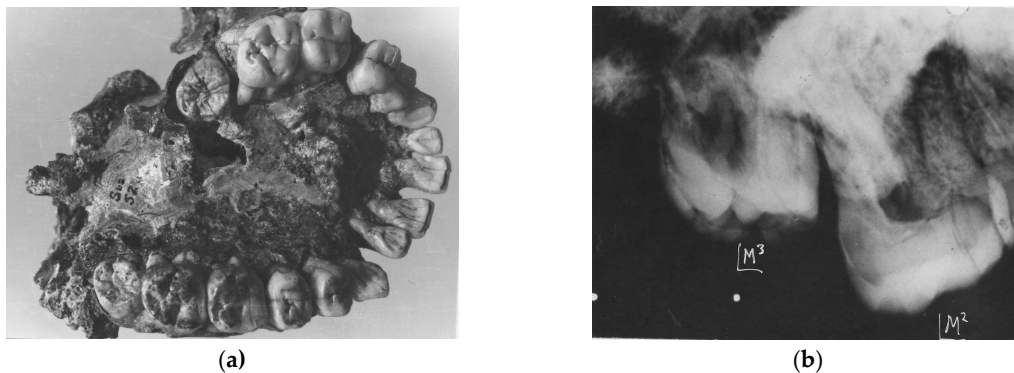


Fig 3. *Australopithecus africanus* Sts52(a). Above. Occlusal view of the complete maxillary dentition (above). Warping of the maxilla has distorted the dental arcade. Moderate occlusal attrition of the M1 molars contrasts with the slight wear on the later erupted M2s and the pristine unerupted M3s. Below. X-ray of left maxillary M2 and unerupted M3.

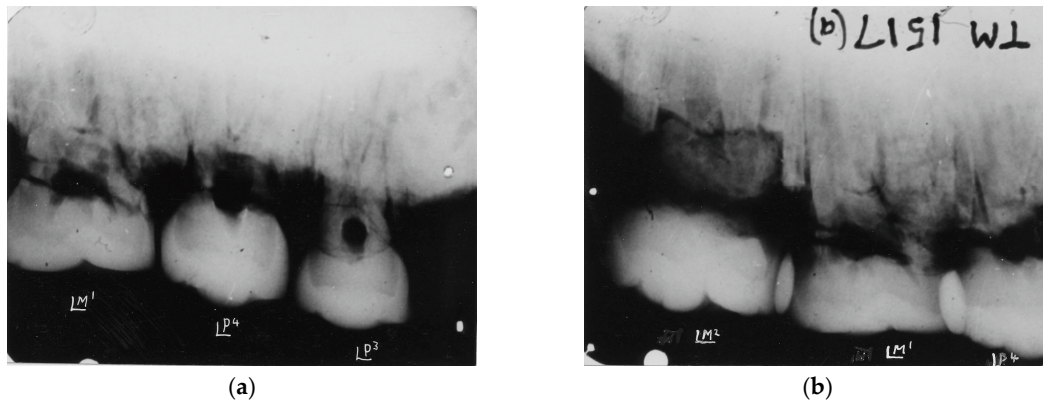


Fig 4. Kromdraai Paranthropus TM 1517 (a). Radiographs of maxillary teeth reveal the graded wear of the premolars and M1 and partial mesial wear of M2.



Fig 5. Kromdraai Paranthropus TM 1600. Isolated mandibular premolar, 1st and 2nd molars exhibiting severe attritional wear attesting to a rough diet.

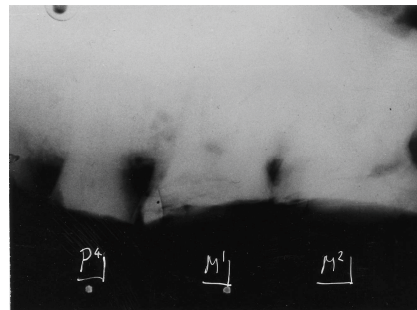


Fig. 6. *Australopithecus africanus* Makapansgat MLD 9. Radiograph of maxillary teeth in situ exhibiting extreme attritional wear of P4, M1 and M2, attesting to a tough abrasive diet early in life.

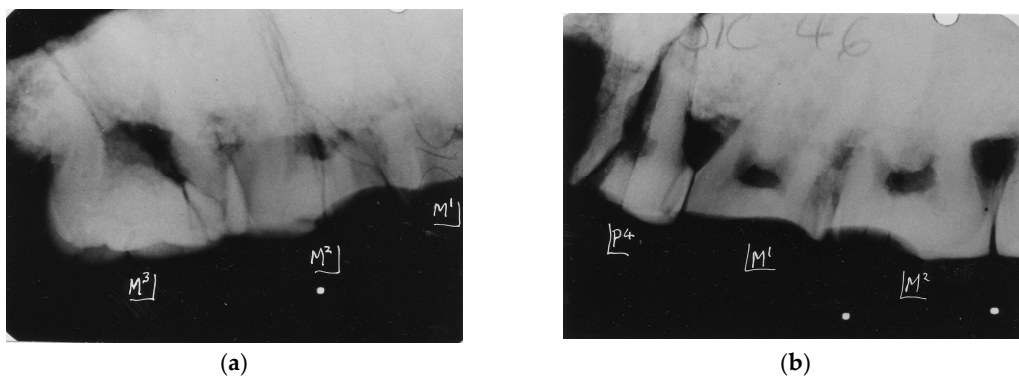


Fig. 7. *Paranthropus robustus*. Kromdraai. SK 46. Above. Radiograph of right maxillary teeth revealing graded wear from M1 (severe) to minor wear on M3.

Below: Left maxillary teeth. An unusual pattern of severe wear confined to the mesial half of M2 is seen that requires some explanation. The less worn distal half of this tooth and M3 suggests absence of the corresponding occluding mandibular M2 and M3. Thereby, unusual wear patterns can reveal peculiar phenomena of attrition.

5. Conclusions

Distinguishing between abrasion and attrition in early hominin dentitions might provide evidence of the nature of dietary components. However, the examples provided here of extreme wear in the comparatively short lifespans of the australopithecines indicate very abrasive diets. Significantly, no evidence of erosive impact characteristic of dental caries was found in any of the specimens examined.

The information that can be gleaned from tooth wear is subject to many interpretations of their etiology by different agents over a lifetime of dental usage. Teeth tell tales long after death prevails, revealing much but not all of the history of the food ingestion experienced by the specimens studied.

References

1. Carvalho, T.S., Colon P., Ganss C. et al. Consensus report of the European Federation of Conservative Dentistry: erosive tooth wear-diagnosis and management. *Clin Oral Invest* (2015) 19:1557-1561.
2. Ranjitkar S., Turan A., Mann C. et al. Surface sensitive microwear texture analysis of attrition and erosion. *J Dent Res* (2017). 96 (3): 300-307.
3. Spee, F.G. Die verschiebungsbahn des unterkiefers am schadel. *Arch Anat Physiol* (1890) 16:285-294.
4. Marshall S.D., Casperson M et al. Development of the curve of Spee. *Am J Orthod Dentofac Orthoped* (2008) 134:344-352.
5. Sun, K, Wang W, Wang X, et al. Tooth wear: a cross-sectional investigation of the prevalence and risk factors in Beijing, China. *BDJ Open* 3. (2017) Article 16012 (2017). doi:101038/bdjopen.2016.12.
6. Molnar S, Gantt D.G. Functional implications of primate enamel thickness. *Am J Phys Anthropol* (1977). 46: 447.
7. Sperber G.H. Comparative primate dental enamel thickness: a radiodontological study. In Tobias PV.(Ed).: "Hominid Evolution: Past, Present and Future". New York. Alan R. Liss, (1985). Pp 443-454.
8. Grine F.E., Sponheimer M, Ungar P. et al. Dental microwear and stable isotopes inform the paleocology of extinct hominins. *Am J Phys Anthropol* (2012). 148:285-317.
9. Lucas P.W., Omar R., Al-Fadhalah K et al. Mechanisms and causes of wear in tooth enamel: implications for hominin diets. *J Roy Soc Interface* (2013). doi:10:20120923.
10. Grine F.E. Trophic differences between "gracile" and "robust" australopithecines: a scanning electron microscopic analysis of occlusal events. *S Afr J Sci* (1981).77: 203.
11. Grine F.E. Dental evidence for dietary differences in *Australopithecus* and *Paranthropus*: a quantitative analysis of permanent molar microwear. *J Hum Evol.* (1986).15:783-822.
12. Scott R.S., Ungar P.S. Bergstrom T.S. et al. Dental microwear texture analysis shows within species dietary variability in fossil hominins. *Nature* (2005). 436: 693-695.
13. Sponheimer M., Passey B.H. de Ruiter D.J. et al. Isotopic evidence for dietary variability in the early hominin *Paranthropus robustus*. *Science* (2006). 314:980-982.
14. Sperber G.H. Morphology of the Cheek Teeth of Early South African Hominids. PhD thesis. (1974). University of the Witwatersrand, Johannesburg, South Africa.