

## Article

# Protective Effects of Astaxanthin Supplementation against Ultraviolet-Induced Photoaging in Hairless Mice

Xing Li, Tomohiro Matsumoto, Miho Takuwa, Mahmood Saeed Ebrahim Shaikh Ali, Takumi Hirabayashi, Hiroyo Kondo and Hidemi Fujino\*

Department of Rehabilitation Science, Kobe University Graduate School of Health Sciences, 7-10-2 Tomogaoka, Suma-ku, Kobe, Hyogo 654-0142, Japan; lixing3633@gmail.com (X.L.); tomo08047777@gmail.com (T.M.); miho.takuwa@gmail.com (M.T); mahmood\_6195@hotmail.com (M.S.E.S.A.); hirabayashitkm1@gmail.com (T.H.); hiroyokondo@gmail.com (H.K.).

\* Correspondence: fujino@phoenix.kobe-u.ac.jp; Tel./Fax: +81-78-796-4542

**Abstract:** Ultraviolet (UV) induces skin photoaging, which is characterized by thickening, wrinkling, pigmentation, and dryness. Astaxanthin, a ketocarotenoid isolated from *Haematococcus pluvialis*, has been extensively studied owing to its possible effect on skin health as well as UV protection. In addition, astaxanthin attenuates increases in the generation of reactive oxygen species (ROS) and capillary regression of skeletal muscle. In the present study, we investigated whether astaxanthin would protect UV-induced photoaging and reduce capillary regression in the skin of HR-1 hairless mice. UV induces wrinkle formation, thickening, and capillary regression in the dermis of hairless mice; the administration of astaxanthin reduced UV-induced wrinkle formation, skin thickening, and increase in collagen fibers in the skin. Astaxanthin supplementation also inhibited ROS generation and attenuated the decreases in wrinkle formation, thickness, and capillary number in the skin. We also found an inverse correlation between wrinkling and capillary number and an association between photoaging and capillary regression in the skin. These results suggest that astaxanthin can protect against photoaging caused by UV irradiation and that the inhibitory effects of astaxanthin on photoaging may be associated with the reduction of capillary regression in the skin.

**Keywords:** astaxanthin; antioxidant; skin; ultraviolet; photoaging; capillary

## 1. Introduction

The skin is the largest organ in mammals, consisting of predominantly of an external stratified, non-vascularized, epithelium (epidermis); the underlying connective tissue (dermis); and the subcutaneous adipose tissue called the hypodermis. The skin can regulate the local and global homeostasis by sensing the environment [1-2]. However, prolonged exposure to ultraviolet (UV) irradiation causes photoaging, which is clinically characterized by dryness, deep wrinkling, laxity, and pigmentation [3,4].

A recent study showed that exposure of the skin to UV radiation induces reactive oxygen species (ROS) generation, accompanied by the expression of genes and proteins, leading to photodamage and photo-carcinogenesis [5]. ROS also cause degradation of dermal collagen and elastic fibers [6].

It is known that oxidative stress, initiated by ROS, as well as DNA damage is induced in skin cells by UV radiation; these damages eventually leads to premature skin photoaging. In addition. The results are fine wrinkles due to diminished or defective synthesis of collagen and elastin in the dermis [4,7].

Astaxanthin (AST), which naturally exists in seafood such as shrimp and salmon, and as well as in *Haematococcus pluvialis* (*H. pluvialis*), and is a red-colored pigment that is affiliated to the xanthophyll subclass of carotenoids and that can scavenge ROS [8]. ASTs are characterized by a great variety of advantageous

biological activities, promoting favorable outcomes. These include protection against UV-induced cell damage, and chronic inflammatory diseases, and the promotion of immunomodulatory activities, alleviation of metabolic syndrome, cardioprotective effects, antidiabetic activity, inhibition of neuronal damage, anti-aging effects on the skin, and anticancer activity, as well as the suppression of cell membrane peroxidation [5,9]. AST has been demonstrated to accelerate skin health by direct and downstream consequences at different steps of the oxidative stress cascade in skin [10]. In addition, several clinical studies it have reported on the effects of astaxanthin on photoaging in the skin [11-12]. AST supplementation has significant anti-aging and functional improvements of the skin in healthy women [13]. It has also been reported astaxanthin supplementation improves crow's feet wrinkle, elasticity and transepidermal water loss in the skin of healthy women.[14]. Thus, AST has profound utility. However, the effect of AST on capillaries in the skin has rarely been reported. Therefore, the aim of the present study was to investigate whether AST could prevent UV-induced epidermal thickening, ROS generation, and reduce capillary regression in the skin of HR-1 hairless mice.

## 2. Materials and Methods

### 2.1. Animals

Male HR-1 hairless mice aged 6 weeks old were procured and acclimated for 2 weeks before the starting the experiments. The mice were housed at 22 °C under a 12 h dark/light cycle and were fed a commercial diet and allowed access to tap water ad libitum throughout the study. All experiments procedure were in compliance with the Institution Animal Care and Use Committee and followed the Kobe University Animal Experimentation Regulations. All experiments were conducted in accordance with the National Institute of Health Guide for the Care and Use of Laboratory Animals (National Research Council, (approval code: P180802, 2018).

### 2.2. Astaxanthin Treatment

The HR-1 hairless mice were divided randomly into three groups (n = 8 per group): astaxanthin was implemented to the mice for 8 weeks, 100 mg/kg/daily, (1) control, oil olive oil alone (CON), (2) UV-induced plus oil olive (UV), (3) UV-induced plus AST. In the AST was administered to the mice for 8 weeks, 100mg/kg daily. This study was approved by the Institution Animal Care and Use Committee and followed the Kobe University Animal Experimentation Regulations (Kobe, Japan). All experiment and animal care programs were managed in conformity to the Guide for the Care and Use of Laboratory Animals published by the US National Institutes of Health (NIH publication no. 85-23, revised 1996).

### 2.3. UV Irradiation

UV irradiation of mice was performed using a UV lamp (Lutron UV-340A, Taipei, Taiwan) with an emission control spectrum between 365 and 400 nm. A UV meter (Lutron UV-340A, Taipei, Taiwan) was used for the measurement of UV irradiance. The UV lamp was situated 20 cm above the dorsal skin of the mice. UV light was applied to the mice for 8 weeks, and the amount of irradiance was gradually increased from 1 up to 4 MED (1 MED = 1 minimal erythema dose = 100 mJ/cm<sup>2</sup>) with no injury. The dorsal skin of the mice was exposed to UV light 3 times/week at 1 MED for the first 2 weeks, 2 MED 3 times/week for 2 weeks, 3 MED 2 times/week for 2 weeks, and 4 MED 3 times/week for 2 weeks [15].

#### 2.4. Wrinkle Measurement

Skin condition was evaluated by taking photographs of the mouse dorsal skin at the end of the eight week to confirm the extent of wrinkle formation. Replicas were prepared using a SILFLO kit (CuDerm Corporation, Dallas, TX, USA) to scale the area of the wrinkles just before harvesting the skin of the mice.

#### 2.5. Histological Analysis and Collagen Staining

The dorsal skin of the mice located, between the ilia was harvested at the end of the experiment at an age of 16 weeks after application of anesthesia. The skins were dipped and fixed in 4% paraformaldehyde and 30- $\mu$ m thick cryosections were prepared. Hematoxylin staining was performed to examine histological features and epidermal and dermal thickness. After mounting in mounting medium (Vector Laboratories, Inc., Burlingame, CA, USA), images were captured using an Axio Imager A1 microscope (Carl Zeiss Inc., Göttingen, Germany). IMT i-solution (IMT i-solution Inc., Vancouver, BC, Canada) was used for automatic measurement analysis of each staining.

#### 2.6. Masson Stain

For histological analysis and collagen staining, the dorsal skin of the mice between the ilia was harvested under anesthesia at the end of the experiment at an age of 16 week-old mice. The skins were immersed and fixed in 4% paraformaldehyde and 30- $\mu$ m thick cryosections were prepared. Hematoxylin staining was performed to examine histological features and epidermal and dermal thickness. Masson's trichrome staining was performed using Masson's trichrome staining kit (Abcam, Cambridge, MA, USA) to examine the density of collagen fibers. After mounting in mounting medium (Vector Laboratories, Inc., Burlingame, CA, USA), images were captured using an Axio Imager A1 microscope (Carl Zeiss Inc., Göttingen, Germany). IMT i-solution (IMT i-solution Inc. Vancouver, BC, Canada) was used for an automatic measurement analysis of each staining.

#### 2.7. Assessment of ROS

In situ detection of ROS was evaluated using oxidative fluorescent dihydroethidium (DHE), which emits light when it interacts with  $O_2$  to form oxyethidium. Dihydroethidium is a cell-permeable agent and interacts with nucleic acids to emit a light red color qualitatively detectable by fluorescence microscopy (BX51; Olympus, Tokyo, Japan) with a rhodamine filter (excitation, 490 nm; emission, 590 nm). This staining method has been previously used to determine ROS activity (Whitehead et al. 2008; Bouitbir et al., 2011; Cozzoli et al., 2011; Kanazashi et al., 2013). Briefly, the sections (30  $\mu$ m thick) were incubated with  $5 \times 10^{-6}$  mol  $L^{-1}$  DHE (Wako Pure Chemicals, Osaka, Japan) for 30 min at 37 °C in a dark box, rinsed with 37 °C PBS, and observed using a fluorescence microscope (filter with excitation at 545 nm). Densitometric analysis of DHE fluorescence was performed using the ImageJ software (NIH, Bethesda, MD, USA) using five images per skin, and results were reported as a percentage of the control group. The individuals performing the densitometric analyses of fluorescence were blinded to the experimental groups. There may be some limitations with this technique (Laurindo et al., 2008; Kalyanaraman et al., 2014). For example, freezing and cutting muscle sections that are warmed in the presence of DHE could artificially release reactive oxygen species. However, this potential problem was minimized because all the tissues were prepared in a similar manner.

#### 2.8. AP Staining

The sections were stained with alkaline phosphatase (AP) as previously described to observe the capillarity of the soleus muscles [36]. Briefly, the sections were incubated in 5-bromo-4-chloro-3-indolyl phosphate/nitro blue tetrazolium for 45 min at 37 °C and fixed with 4% paraformaldehyde. The number of capillaries was determined by counting capillaries on each cryosection using the microscopic images.

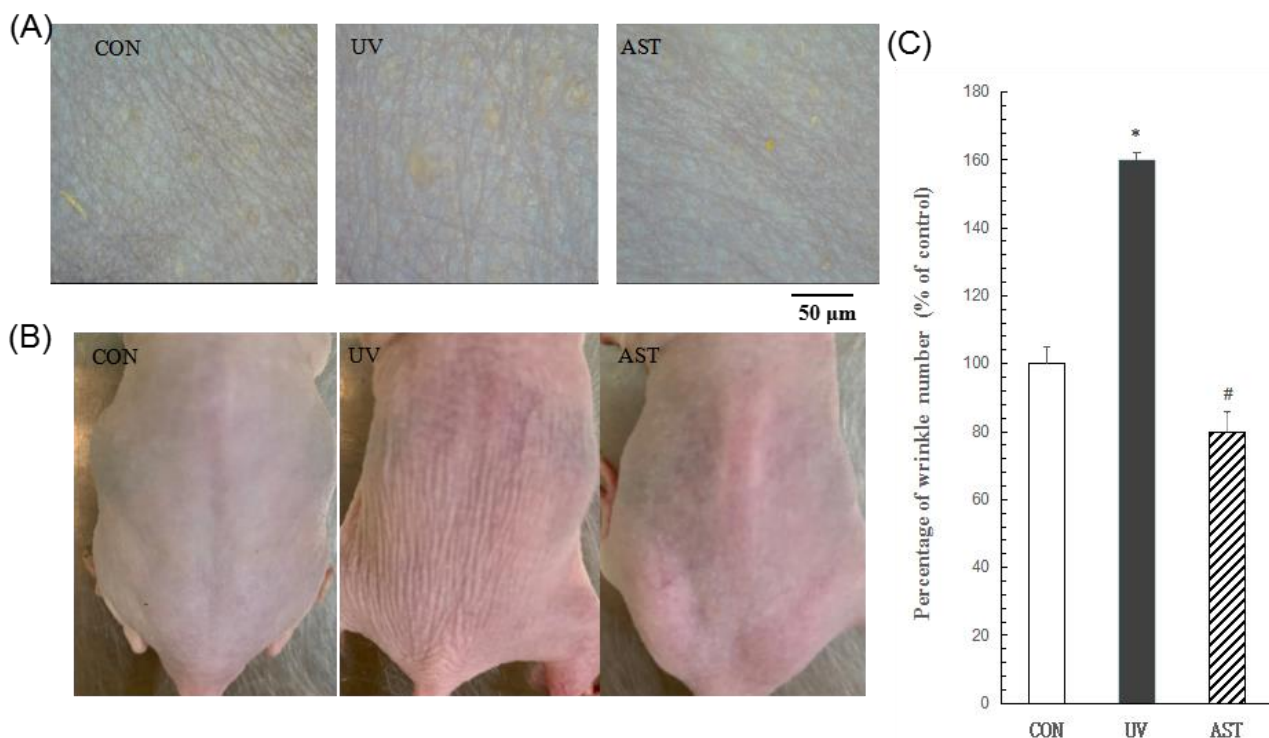
## 2.9. Statistical Analysis

Data are presented as the mean  $\pm$  SD. Statistical analyses were carried out by one-way ANOVA followed by the Scheffe test. Differences were considered significant when  $p < 0.05$ .

## 3. Results

### 3.1. The Effects of AST on Wrinkle Formation in UV-Induced Hairless Mice

Skin conditions revealed by photography showed that the dorsal skin of UV-induced mice was lumpy and flaky compared with that of the control mice (Figure 1B). However, decreased flakiness and roughness were decreased in UV-induced mice treated with AST compared to that in mice exposed to UV irradiation alone. An analysis of wrinkle formation in silicon replicas revealed that the wrinkles of the control mice were thin and shallow (Figure 1A), while those of the UV-induced mice were thick. Moreover, the UV-induced mice showed an increase in the percentage area of wrinkles compared with that observed for the control mice. These changes were reduced by AST treatment (Figure 1C). An analysis showed that AST may reduce UV-induced wrinkle formation.



**Figure 1.** (A) The effects of astaxanthin on the dorsal skin of ultraviolet(UV)-induced mice. (B) Photographs of the mouse dorsal skin. Scale bar = 200  $\mu$ m. (C) Histograms of the replica analysis. Treatment with astaxanthin improved visible skin condition, reduced the percentage of wrinkles per unit area, and the mean area of wrinkles in UV-induced mice. \*  $p < 0.01$  and #  $p < 0.01$  vs. control mice; #  $p < 0.01$  vs. UV-induced mice.

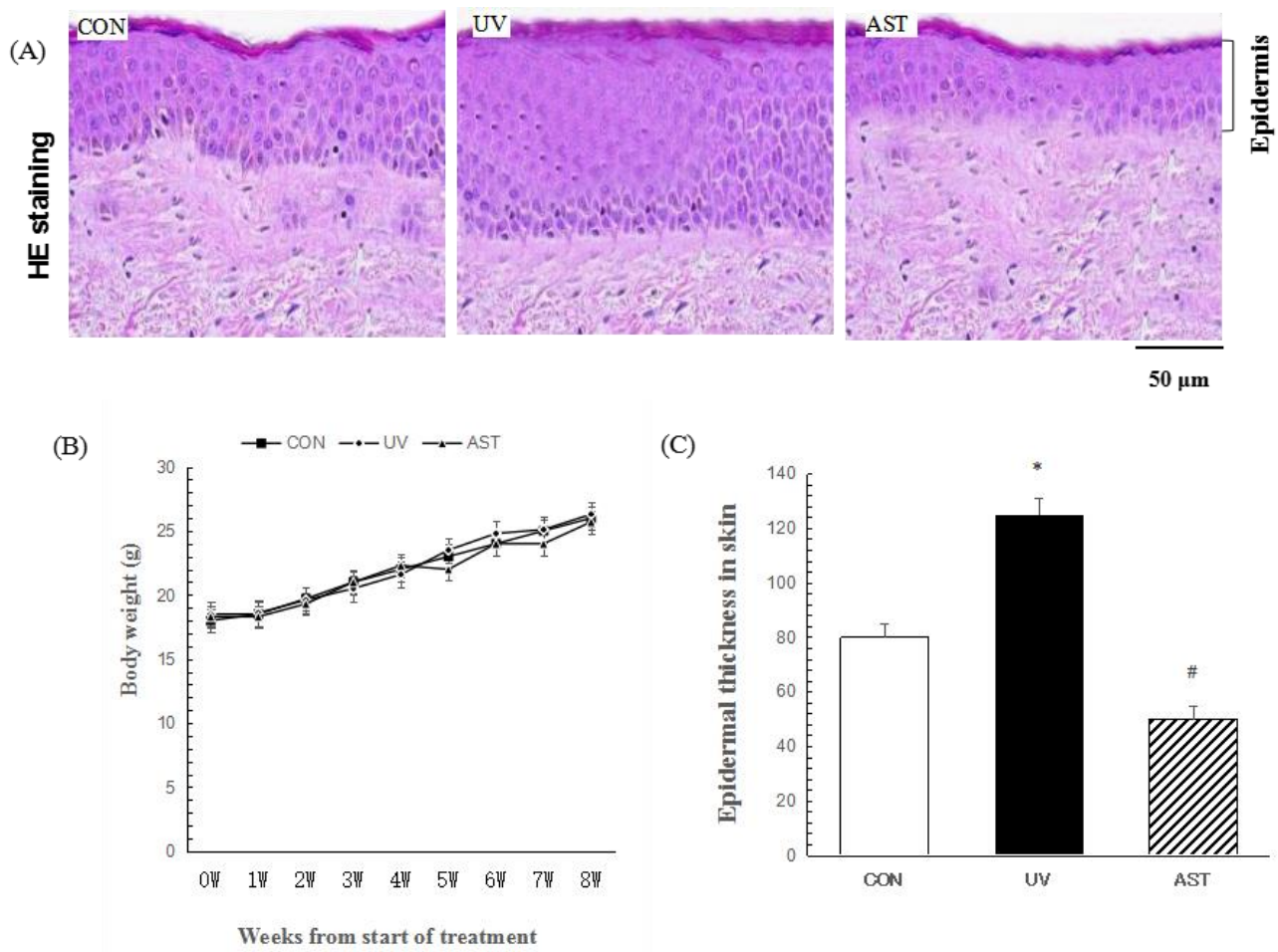
### 3.2. The Effect of AST on Epidermal Thickness in the Dorsal Skin of UV-Induced Mice

In this study, we evaluated the dorsal skin sections via H&E staining (Figure 2A). The thickness of the epidermis is generally used as a parameter to reveal photoaging in skin. In this study, we investigated UV-induced skin photoaging in a HR-1 mouse model. None of the treatments revealed any evident signs of toxicity as determined by the loss of body weight (Figure 2B). In order to investigate the effects of AST on the



photoaging of skin in vivo, the HR-1 mice were irradiated with UV. H&E staining revealed the effects of AST on histological changes of in the dorsal skin (Figure 2A).

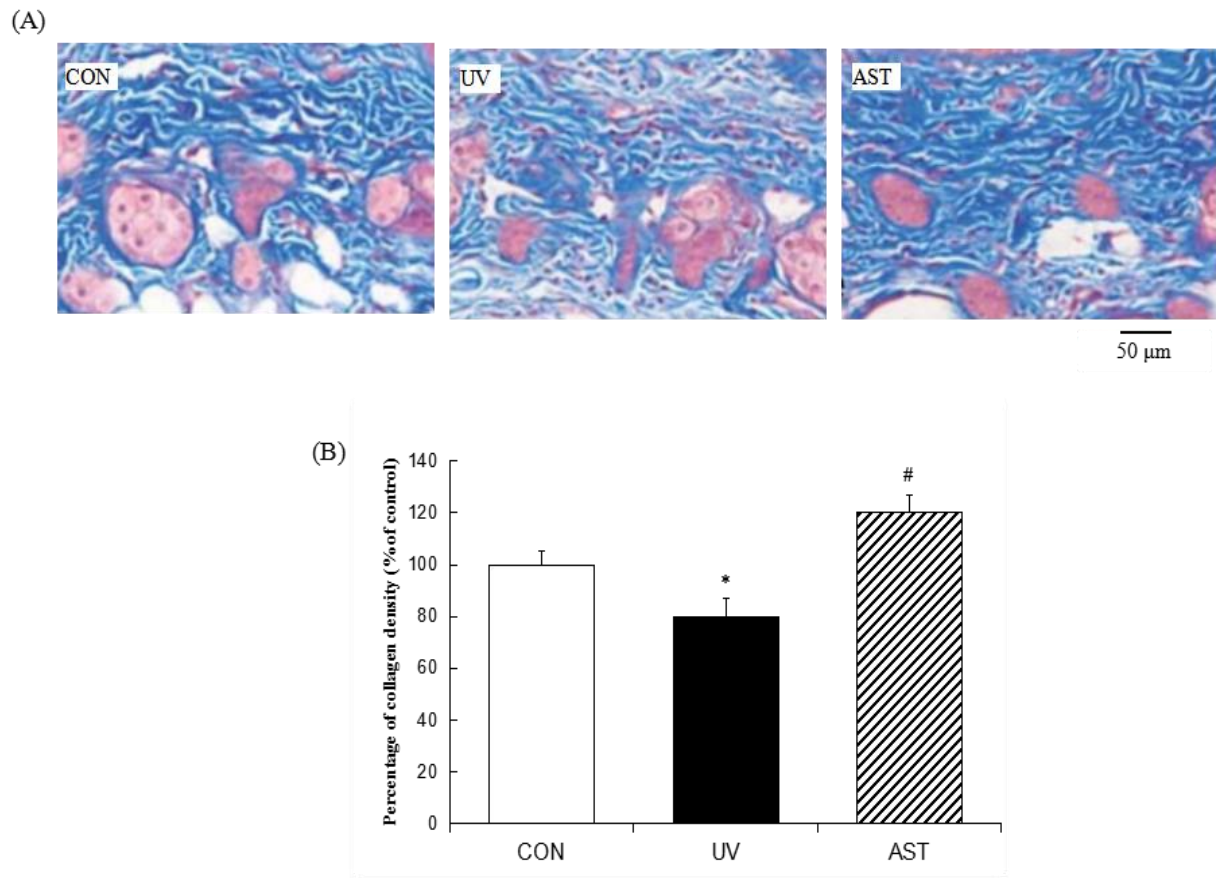
As expected, the UV-induced mice had thicker epidermal layers than the mice (control group) that were not induced by UV. However, the control mice and the AST-treated mice had thinner epidermal layers than the mice that were only irradiated with UV (Figure 2C).



**Figure 2.** The effect of astaxanthin on epidermal thickness in the dorsal skin of UV-induced mice. (A) Hematoxylin and eosin staining. Scale bar = 50  $\mu$ m. (B) Measurement of body weight in hairless mice, taken once per week. (C) Histogram of hematoxylin and eosin staining. Treatment with astaxanthin significantly suppressed the UV irradiation-induced increase in epidermal thickness. \*  $p < 0.01$  vs. control mice; #  $p < 0.01$  vs. UV-induced.

### 3.3. Effect of Astaxanthin on the Density of Collagen Fibers in the Dorsal Skin of UV-Irradiated Hairless Mice

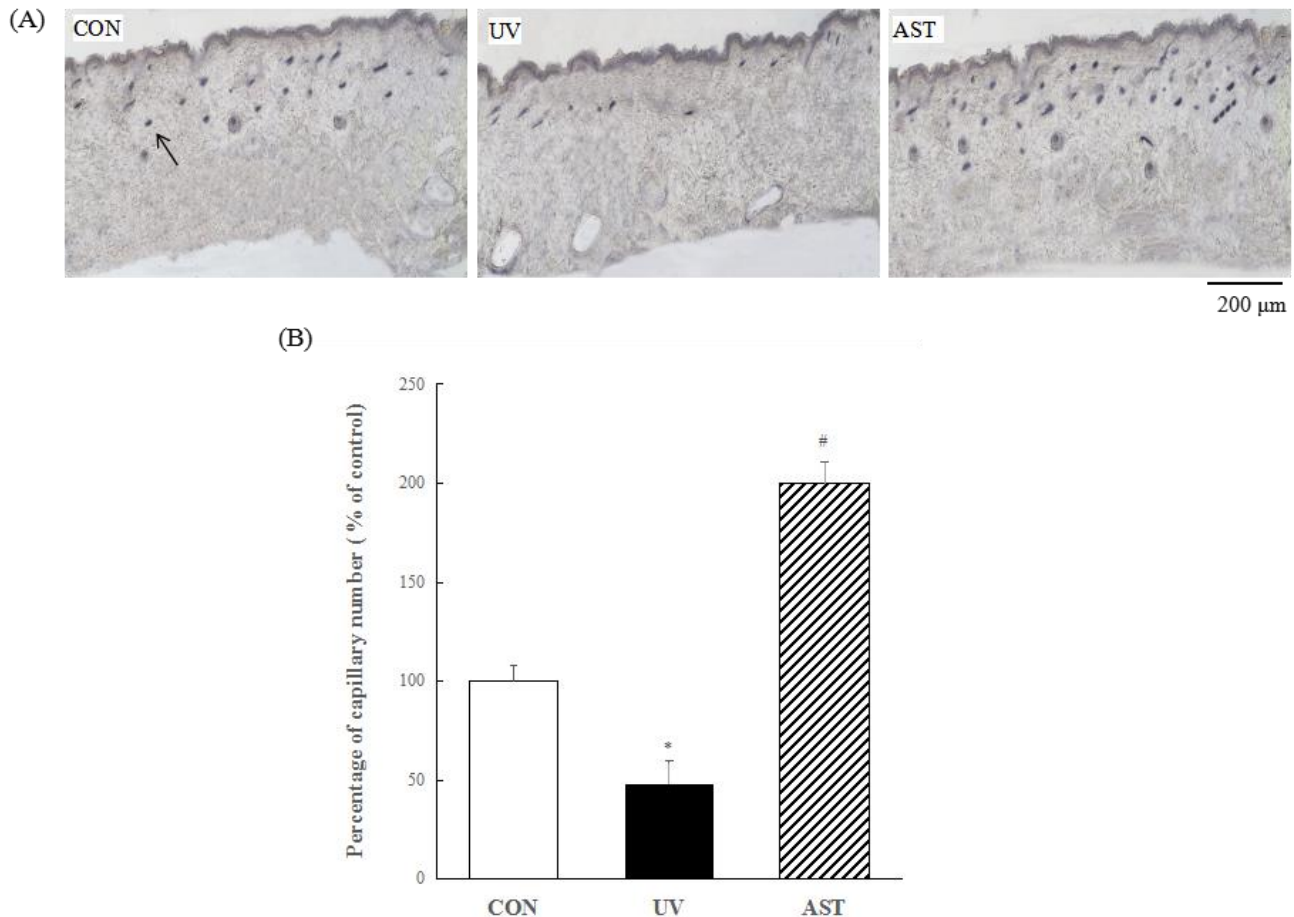
The changes in collagen in the dermis of hairless mice were investigated in UV-irradiated mice treated with AST. Masson's trichrome staining showed the effects of AST on histological changes in the dorsal skin (Figure 3A). We found a significant reduction in the density of collagen fibers in the dermis of UV-irradiated hairless mice compared to that in the control hairless mice. Nevertheless, treatment with AST restrained the UV irradiation-induced loss of collagen fibers (Figure 3B). These results show that AST can reduce UV irradiation-induced skin collagen fiber loss, indicating the protective effect of AST against UV-induced skin damage.



**Figure 3.** The effect of astaxanthin on density of collagen fibers in the dorsal skin of ultraviolet (UV)-induced mice. (A) Masson's trichrome staining. Scale bar = 50  $\mu$ m. (B) Treatment with astaxanthin significantly suppressed the UV irradiation-induced reduction in collagen-fiber density by preventing the UV-induced loss of collagen fibers \*  $p < 0.01$  vs. control mice; #  $p < 0.01$  vs. UV-induced mice.

#### 3.4. Effect of AST on Changes in the Number of Capillary Vessels in the Dorsal Skin of UV-Induced Mice

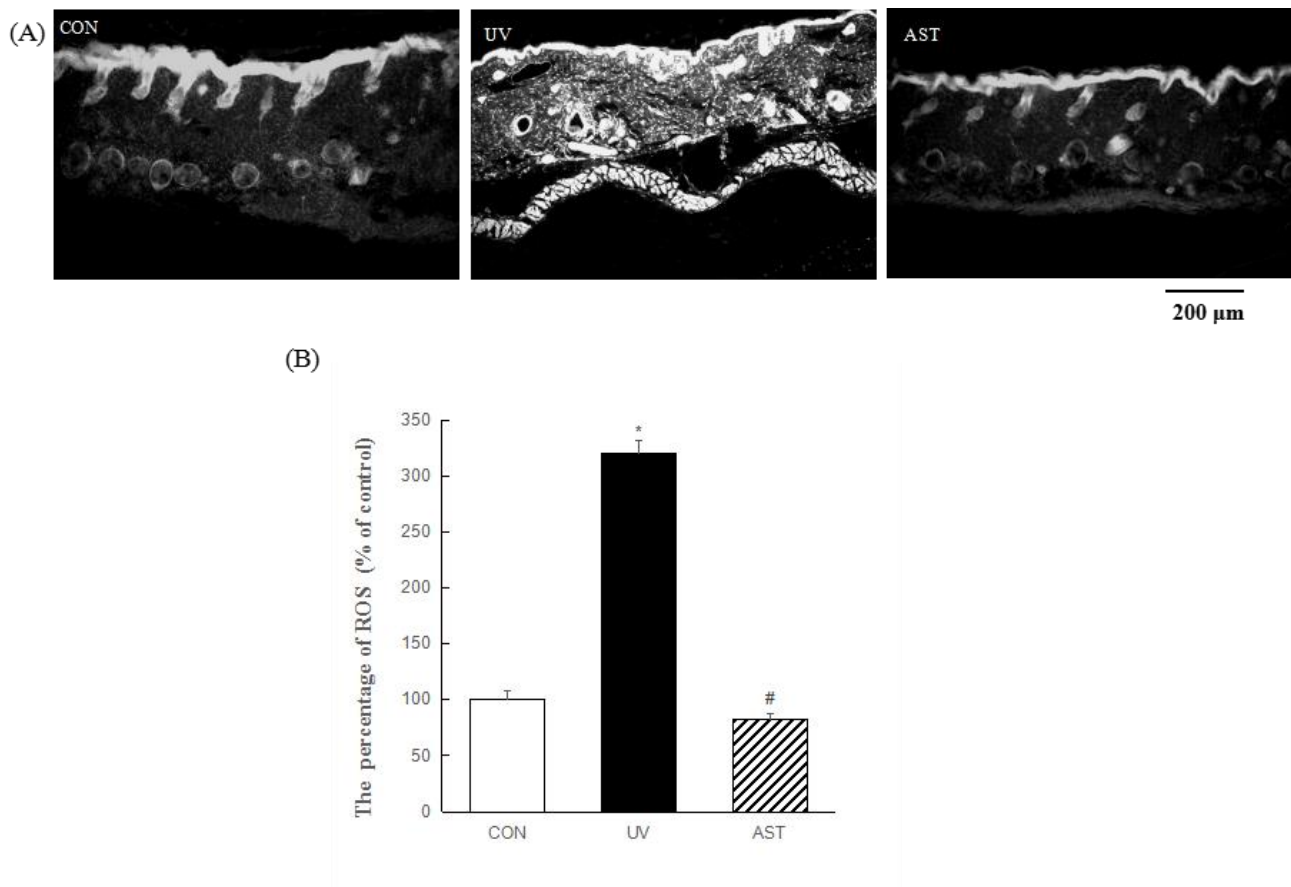
In order to investigate the changes of the capillaries in the dorsal skin of UV-induced mice, AP staining was used to evaluate the presence and distribution of capillaries. As shown in Figure 4A, there were fewer capillaries in UV-induced mice than in non-induced mice. We also found that the AST group showed an increased number of capillaries compared with the UV group (Figure 4B). In this study, the results show that the number of capillary vessels was reduced in the dorsal skin of UV-induced mice; however, the changes can be reversed by oral AST.



**Figure 4.** The effect of astaxanthin on changes in the number of capillary vessels in the dorsal skin of ultraviolet (UV)-induced mice. (A) AP staining. Scale bar = 200 μm. (B) Treatment with astaxanthin significantly suppressed the UV irradiation-induced loss of capillary vessel (Arrow pointing). \*  $p < 0.01$  vs. control mice; #  $p < 0.01$  vs. UV-induced mice.

### 3.5. Effect of AST on ROS Activity in the Dermis and Capillary Vessels in the Dorsal Skin of UV-Induced Mice

A marked enhancement in total ROS activity, as measured using DHE, was observed in UV-induced hairless mice compared to that in control hairless mice (Figure 5A). Nevertheless, AST significantly reduced UV-induced ROS formation (Figure 5B). We determined the distribution of ROS in the skin and noted that UV-induced hairless mice exhibited significantly increased ROS generation, not only in the epidermis but also in the dermis. However, treatment with AST led to a significant reduction in UV-induced ROS generation (Figure 5B). The significant reduction in ROS in the skin, especially in the epidermis, blood vessels, cellular components of the dermis, and the extracellular matrix, shows that AST reduces UV-induced generation of ROS.

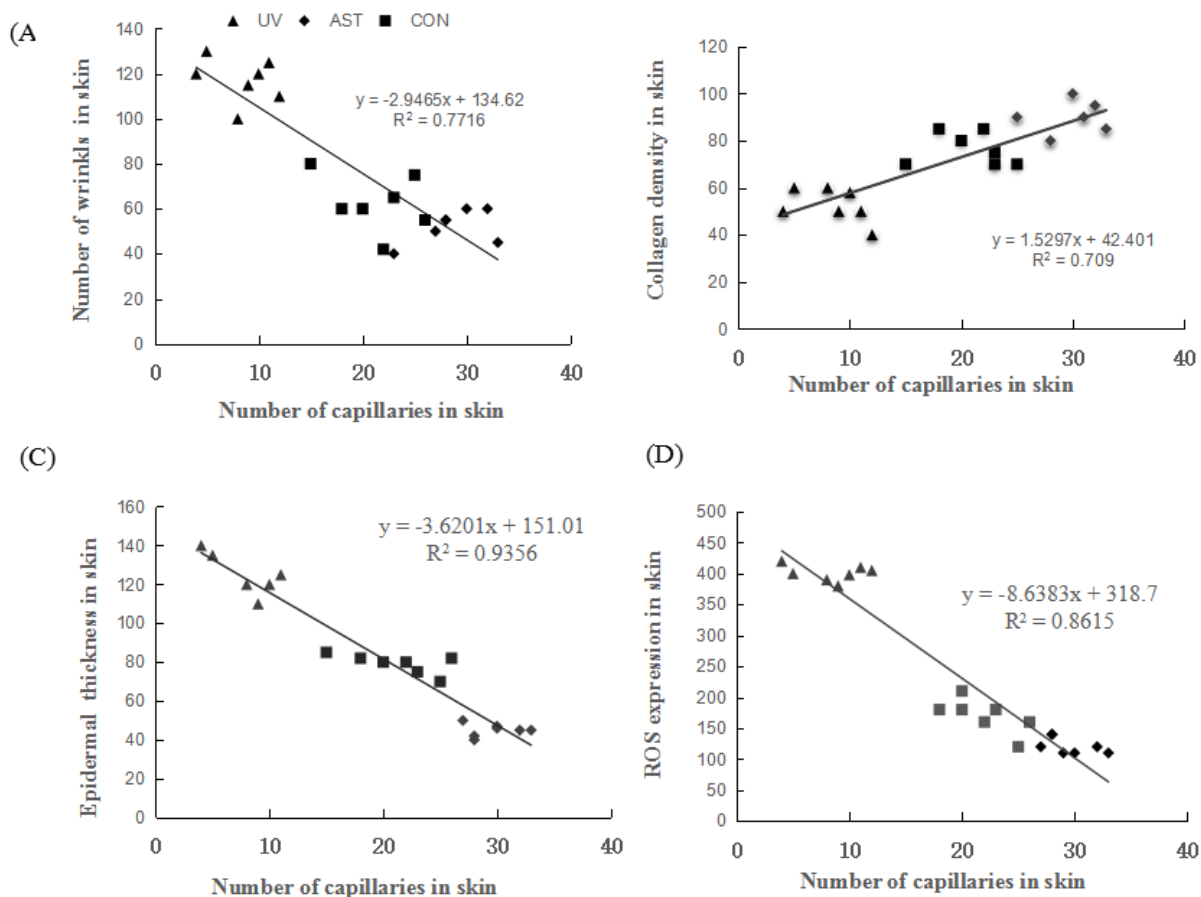


**Figure 5.** The effect of astaxanthin on ROS generation in the epidermis and capillary vessels in the dorsal skin of ultraviolet (UV)-induced mice. **(A)** Fluorescent staining. Scale bar = 200 μm. **(B)** Treatment with astaxanthin significantly suppressed the UV irradiation-induced increase in ROS in the dorsal skin of UV-induced mice. \*  $p < 0.01$  vs. control mice; #  $p < 0.01$  vs. UV-induced mice.

### 3.6. The Correlation between the Number of Capillaries and Epidermal Thickness, Collagen Density, and ROS Generation in the Dorsal Skin of UV-Induced Mice

We also investigated the relationship between capillaries and epidermal thickness, collagen, and ROS. We found that the number of capillaries is negatively correlated with the number of wrinkles, thickness of the epidermis and ROS levels (Figure 6A,C,D). The number of capillaries is positively correlated with collagen density (Figure 6B). This shows that changes in the number of capillaries have an important effect on the photoaging of dorsal skin in UV-induced mice.





**Figure 6.** (A) The correlation between the number of capillaries and epidermal thickness, collagen density, and ROS generation in the dorsal skin of ultraviolet (UV)-induced mice. (B) The number of capillaries is negatively correlated with the thickness of the epidermis. (C) The number of capillaries is positively correlated with collagen density. (D) The number of capillaries is negatively correlated with the reactive oxygen species (ROS) expression.

#### 4. Discussion

The novel findings of this study are as follows: (i) capillary regression was observed in the UV-induced photoaging skin of hairless mice, and this was accompanied by an increase in ROS generation; (ii) AST supplementation attenuated skin photoaging, which is characterized by skin thickening and wrinkling, and maintained ROS levels and capillary number at control levels; (iii) changes in the number of capillaries were observed in the skin of hairless mice, which have close correlation with wrinkles, collagen density, epidermal thickness, and ROS levels. Thus, AST treatment was demonstrated as a protective therapy for skin photoaging.

Changes in the skin are the most prominent signs of aging. Skin aging can be divided into intrinsic or chronologic aging, which is the process of senescence that affects all body organs and extrinsic aging, e.g., photoaging, which occurs because of exposure to environmental factors.

One of the most important factors influencing intrinsic aging is a gradual loss of function or degeneration that occurs at the cellular level [16]. The exposure of the skin to UV irradiation induces the generation of reactive oxygen/nitrogen species or oxidative stress, which is capable of oxidizing lipids, proteins, and DNA.

The resulting oxidized products, including lipid hydroperoxides, protein carbonyls, and 8-hydroxydeoxyguanosine, have been implicated in the onset of skin aging [17-18]. Thus, UV induces ROS, primarily formed via oxidative cell metabolism, and plays a major role in both chronological aging and

photoaging of skin [19]. In addition, UV leads to an increase in epidermal thickness, termed hyperkeratosis, and induces damage response pathways in keratinocytes. After several hours of UV exposure, however, robust proliferation of epidermal keratinocytes occurs, which is mediated by a variety of epidermal growth factors [20]. The increase in keratinocyte cells after UV exposure leads to an accumulation of epidermal keratinocytes, which increases epidermal thickness. In the present study, UV irradiation also resulted in an increase in epidermal thickness in the exposed dorsal skin of mice (Figure 2). Thus, UV-induced oxidative cutaneous damage may play a major role in photoaging. UV may inactivate carotenoids in the skin and promote degradation of dermal collagen and elastin [21-22]. In addition, UV radiation has been reported to promote the activation of enzymes that destroy elastic fibers and collagen, making the skin more prone to wrinkling [23].

In the present study, we also confirmed wrinkle formation (Figure 1), epidermal thickening (Figure 2), and a reduction in collagen (Figure 3) caused by UV irradiation in hairless mice. Furthermore, Shin et al. noted an inverse correlation between wrinkling and important antioxidant enzymes that reduce the cellular levels of ROS [24]. In a recent study, it was reported that the increase in ROS generation and oxidative stress led to vascular lesions, identified at the early stage of diabetic retinopathy, which included the obliteration of capillaries and small arterioles, gradual thickening of the vascular basement membrane, increase in permeability of vessels due to leakage, and hemorrhage [25].

It has also been reported that the reductions in capillary diameter and volume are associated with vascular endothelial cell apoptosis via increased oxidative stress [26]. Furthermore, in UV-induced skin, the dermal thickness increased while the capillary density decreased, as recently reported by Deng et al. [27]. We also found an inverse correlation between wrinkling and the levels of ROS and between wrinkling and the capillary number in the skin of mice (Figure 6). Thus, photoaging may be associated with capillary regression in skin.

Meanwhile, AST inhibits ROS formation and modulates the expression of oxidative stress-responsive enzymes, such as heme oxygenase-1 (HO-1), which is a marker of oxidative stress and a regulatory mechanism involved in cell adaptation against oxidative damage [28]. It has also been reported that AST decreases the level of oxidative stress, as indicated by reduced plasma malondialdehyde levels, and reverses age-related changes in the residual skin surface components of middle-aged subjects [29].

In the present study, AST supplementation suppressed the levels of ROS generation in the UV-induced photoaging skin of hairless mice (Figure 5). AST has been reported to increase the expression of collagen by inhibiting the expression of MMP-1 and MMP-9 protein in an animal model [30]. Hyun-SunYoon et al. have reported that dietary AST supplementation for 12 weeks increased collagen levels in human skin [31].

AST can effectively suppress in vitro cell damage caused by free radicals and the induction of MMP-1 protein in the skin after UV irradiation [32]. In addition, AST increased collagen content through inhibition of MMP-1 and MMP-3 protein expression in human dermal fibroblasts [33]. In this study, we also found that dietary supplementation with AST for 8 weeks effectively prevented photoaging, including increase in wrinkle formation (Figure 1) and decrease in collagen in the dorsal skin of mice exposed to UV-irradiation (Figure 3); this effect was related to the suppression of ROS in the skin.

Skin capillaries serve an important function by supplying nutrients to the skin. A reduced density of peritubular capillaries was observed in mice subjected to unilateral ureteral obstruction; the density was significantly increased by AST treatment [34]. In addition, a previous study revealed that AST could prevent capillary regression in atrophied soleus muscles by upregulating VEGF protein and downregulating TSP-1 protein [35]. The data from the present study also indicate that the number of capillaries was markedly reduced after exposure to UV, whereas oral administration with AST prevented the decrease in capillaries in the skin of mice (Figure 5). In addition, we found that the number of capillaries is negatively correlated with ROS and epidermal thickness and positively correlated with collagen. AST supplementation prevented the generation of ROS and capillary regression in the skin of HR-1 hairless mice.

Overall, our study indicates the protective effects of dietary AST against photoaging induced by UV radiation, such as reducing wrinkling and preventing a reduction in collagen density and capillary number in the skin.

We found that dietary AST accumulates in the skin and may prevent the effects of UV irradiation on the dermal capillaries as well as on the epidermis thickness. Our results demonstrate the potential of AST to be further developed as a nutraceutical against photoaging.

## 5. Conclusions

Antioxidants are important nutrients that help combat oxidative stress by removing ROS and promoting a healthy oxidative balance. Through the antioxidant defense system, ROS-triggered oxidative damage to biomolecules is controlled, allowing the restrained ROS to do their useful work in physiological cellular responses.

AST stands apart from other antioxidants because of its unique chemical properties. AST is a valuable functional ingredient that supports skin health and expands our healthy aging options. Avoiding an excess of ROS, adopting a healthy lifestyle, and introducing AST into the diet and cosmetics can help prevent oxidative stress. Dietary supplements and functional foods are good sources for increasing the daily intake of AST. This is a promising strategy for maintaining good health and well-being and offers exciting opportunities for the nutraceutical industry.

## Reference

1. Blanpain, C.; Fuchs, E. Epidermal homeostasis: A balancing act of stem cells in the skin. *Nat. Rev. Mol. Cell Biol.* **2009**, *10*, 7–17, doi:10.1038/nrm2636.
2. Baker, Ruth E.; Murray, P.J. Understanding hair follicle cycling: A systems approach. *Curr. Opin. Genet. Dev.* **2012**, *22*, 607–612, doi:10.1016/j.gde.2012.11.007.
3. Gilchrist, B.A.; Yaar, M. Ageing and photoageing of the skin: Observations at the cellular and molecular level. *Br. J. Dermatol.* **1992**, *127*, 25–30, doi:10.1111/j.1365-2133.1992.tb16984.
4. Gilchrist, B.A. A review of skin aging and its medical therapy. *Br. J. Dermatol.* **1996**, *135*, 867–875, doi:10.1046/j.1365-2133.1996.d01-1088.x
5. Kidd, P. Astaxanthin, cell membrane nutrient with diverse clinical benefits and anti-aging potential. *Altern. Med. Rev.* **2011**, *16*, 355–364.
6. Brenneisen, P.; Sies, H.; Scharffetter-Kochanek, K. Ultraviolet-B irradiation and matrix metalloproteinases: From induction via signaling to initial events. *Ann. N. Y. Acad. Sci.* **2002**, *973*, 31–43.
7. Sarasin, A. The molecular pathways of ultraviolet-induced carcinogenesis. *Mutat. Res.* **1999**, *428*, 5–10, doi:10.1016/S1383-5742(99)00025-3.
8. Yuan J.P., Peng J., Yin K., Wang J.H. Potential health-promoting effects of astaxanthin: A high-value carotenoid mostly from microalgae. *Mol. Nutr. Food Res.* **2011**;55:150–165.
9. Ambati, R.R.; Phang, S.M.; Ravi, S. Astaxanthin: Sources, extraction, stability, biological activities and its commercial applications—A review. *Mar. Drugs* **2014**, *12*, 128–152.
10. Komatsu, T.; Sasaki, S.; Manabe, Y.; Hirata, T.; Sugawara, T. Preventive effect of dietary astaxanthin on UV-induced skin photoaging in hairless mice. *PLoS ONE* **2017**, *12*, e0171178.
11. Kielty C.M., Sherratt M.J., Shuttleworth C.A. Elastic fibers. *J. Cell Sci.* **2002**;115:2817–2828. *PLoS ONE*. **2017**;12:e0171178.
12. Lorencini, M.; Brohem, C.A.; Dieamant, G.C.; Zanchin, N.I.; Maibach, H.I. Active ingredients against human epidermal aging. *Ageing Res. Rev.* **2014**, *15*, 100–115.

13. Kaoru, S.; Miyuki, S.; Yuki, S.; Chiharu, N. Anti-aging and functional improvement effects for the skin by functional foods intakes: Clinical effects on skin by oral ingestion of preparations containing Astaxanthin and Vitamins C and E.
14. Tominaga, K.; Hongo, N.; Karato, M.; Yamashita, E. Cosmetic benefits of astaxanthin on human subjects. *Acta Biochim. Pol.* **2012**, *59*, 43–47, doi:10.1016/j.arr.2014.03.002.
15. Kim, H.N.; Gil, C.H.; Kim, Y.R.; Shin, H.K.; Choi, B.T. Anti-photoaging properties of the phosphodiesterase inhibitor cilostazol in ultraviolet B-induced hairless mice. *Sci. Rep.* **2016**, *6*, 31169.
16. Campisi, J. Aging, cellular senescence, and cancer. *Annu. Rev. Physiol.* **2013**, *75*, 685–705, doi:10.1146/annurev-physiol-030212-183653.
17. Danno, K.; Horio, T.; Takigawa, M.; Imamura, S. Role of oxygen intermediates in UV-induced epidermal cell injury. *J. Investig. Dermatol.* **1984**, *83*, 166–168, doi:10.1111/1523-1747.
18. Mitchell, D.L.; Greinert, R.; de, Gruijl, F.R.; Guikers, K.L.; Breitbart, E.W.; Byrom, M.; Gallmeier, M.M.; Lowery, M.G.; Volkmer, B. Effects of chronic low-dose ultraviolet B radiation on DNA damage and repair in mouse skin. *Cancer Res.* **1999**, *59*, 2875–2884.
19. Fisher, G.J.; Kang, S.; Varani, J.; Bata-Csorgo, Z.; Wan, Y.; Datta, S.; Voorhees, J.J. Mechanisms of photoaging and chronological skin aging. *Arch. Dermatol.* **2002**, *138*, 1462–1470, doi:10.1001/archderm.
20. Coelho, S.G.; Choi, W.; Brenner, M.; Miyamura, Y.; Yamaguchi, Y.; Wolber, R.; Smuda, C.; Batzer, J.; Kolbe, L.; Ito, S.; et al. Short-and long-term effects of UV radiation on the pigmentation of human skin. *J. Investig. Dermatol. Symp. Proc.* **2009**, *14*, 32–35, doi:10.1038/jidsymp.
21. Lademann, J.; Schanzer, S.; Meinke, M.; Sterry, W. Interaction between carotenoids and free radicals in human skin. *Skin Pharmacol. Physiol.* **2011**, *24*, 238–244, doi:10.1159/000326074.
22. Darvin, M.E.; Richter, H.; Ahlberg, S.; Haag, S.F.; Meinke, M.C.; le Quintrec, D.; Doucet, O.; Lademann, J. Influence of sun exposure on the cutaneous collagen/elastin fibers and carotenoids: Negative effects can be reduced by application of sunscreen. *J. Biophoton.* **2014**, *7*, 735–743, doi:10.1002/jbio.201300171.
23. Takema, Y.; Sakaino, Y.; Imokawa, G. Age-related changes in the mechanical properties and thickness of human facial skin. *Br. J. Dermatol.* **1994**, *131*, 641–648, doi:10.1111/j. 1365 - 2133.
24. Shin, M.H.; Seo, J.E.; Kim, Y.K.; Kim, K.H.; Chung, J.H. Chronic heat treatment causes skin wrinkle formation and oxidative damage in hairless mice. *Mech. Aging Dev.* **2012**, *133*, 92–98, doi:10.1016/j.mad.2012.01.006.
25. Hammes, H. Pericytes and the pathogenesis of diabetic retinopathy. *Horm. Metab. Res.* **2005**, *37*, 39–43.
26. Fujino, H.; Kohzuki, H.; Takeda, I.; Kiyooka, T.; Miyasaka, T.; Mohri, S.; Shimizu. Regression of capillary network in atrophied soleus muscle induced by hindlimb unweighting. *J. Appl. Physiol.* **1985**, *98*, 1407–1413, doi:10.2337/diabetes.
27. Deng, M.; Xu, Y.; Yu, Z.; Wang, X.; Cai, Y.; Zheng, H.; Li, W.; Zhang, W. Protective Effect of Fat Extract on UVA-Induced Photoaging in Vitro and in Vivo. *Oxid. Med. Cell. Longev.* **2019**, *2019*, 6146942, doi:10.1155/2019/6146942.
28. Camera, E.; Mastrofrancesco, A.; Fabbri, C.; Daubrawa, F.; Picardo, M.; Sies, H.; Stahl, W. Astaxanthin, canthaxanthin and beta-carotene differently affect UVA-induced oxidative damage and expression of oxidative stress-responsive enzymes. *Exp. Dermatol.* **2009**, *18*, 222–231, doi:10.1111/j.1600-0625.2008.
29. Chalyk, N.E.; Klochkov, V.A.; Bandaletova, T.Y.; Kyle, N.H.; Petyaev, I.M. Continuous astaxanthin intake reduces oxidative stress and reverses age-related morphological changes of residual skin surface components in middle-aged volunteers. *Nutr. Res.* **2017**, *48*, 40–44, doi:10.1016/j.nutres.2017.10.006.
30. Sharma, S.D.; Meeran, S.M.; Katiyar, S.K. Dietary grape seed proanthocyanidins inhibit UVA-induced oxidative stress and activation of mitogen-activated protein kinases and nuclear factor-kappaB signaling in in vivo SKH-1

hairless mice. *Mol. Cancer Ther.* **2007**, *6*, 995–1005, doi:10.1158/1535-7163.

31. Yoon, H.S.; Cho, H.H.; Cho, S.; Lee, S.R.; Shin, M.H.; Chung, J.H. Supplementing with Dietary Astaxanthin Combined with Collagen Hydrolysate Improves Facial Elasticity and Decreases Matrix Metalloproteinase-1 and -2 Expression: A Comparative Study with Placebo. *J. Med. Food* **2014**, *7*, 810–816, doi:10.1089/jmf.2013.3060.
32. Suganuma, K.; Nakajima, H.; Ohtsuki, M. Astaxanthin attenuates the UVA-induced up-regulation of matrix-metalloproteinase-1 and skin fibroblast elastase in human dermal fibroblasts. *J. Dermatol. Sci.* **2010**, *58*, 136–142, doi:10.1016/j.jdermsci.
33. Chou, H.Y.; Lee, C.; Pan, L.; Wen, Z.H.; Huang, S.H.; Lan, C.W.; Liu, W.T.; Hour, T.C.; Hseu, Y.C.; Hwang, B.H.; et al. Enriched Astaxanthin Extract from *Haematococcus pluvialis* Augments Growth Factor Secretions to Increase Cell Proliferation and Induces MMP1 Degradation to Enhance Collagen Production in Human Dermal Fibroblasts. *Int. J. Mol. Sci.* **2016**, *17*, 955, doi:10.3390/ijms17060955.
34. Zhao, J.; Meng, M.; Zhang, J.; Li, L.; Zhu, X.; Zhang, L.; Wang, C.; Gao, M. Astaxanthin ameliorates renal interstitial fibrosis and peritubular capillary rarefaction in unilateral ureteral obstruction. *Mol. Med. Rep.* **2019**, *19*, 3168–3178, doi:10.3892/mmr.
35. Kanazashi, M.; Okumura, Y.; Al-Nassan, S.; Murakami, S.; Kondo, H.; Nagatomo, F.; Fujino, H. Protective effects of astaxanthin on Roudier E, *J Physiol* **588**: 4579–4591, 2010.
36. Capillary regression in atrophied soleus muscle of rats. *Acta Physiol.* **2013**, *207*, 405–415.