

Review

The polymer-based technology in the endovascular treatment of abdominal aortic aneurysms

Gianmarco de Donato ^{*1}, Edoardo Pasqui ¹, Claudia Panzano ¹, Brenda Brancaccio ¹, Gaia Grottola ¹, Giuseppe Galzerano ¹, Domenico Benevento ¹, Giancarlo Palasciano ¹.

¹ Department of Vascular Surgery, University of Siena, Italy.

* Correspondence: Prof. Dr. Gianmarco de Donato, MD, PhD. Associate Professor of Vascular Surgery, Department of Medicine, Surgery and Neuroscience, Vascular Surgery unit. University of Siena, Italy. Tel & Fax: 0039 0577 585123; dedonato@unisi.it

Abstract: An abdominal aortic aneurysm (AAA) is a dilatation of the abdominal aorta that progressively grows till the rupture. Treatment is typically recommended when the diameter is more than 5 cm. The EVAR (Endovascular aneurysm repair) is a miniminvasive procedure that involves the placement of an expandable stent graft within the aorta to treat aortic disease without operating directly on the aorta. For years, stent grafts' essential design was based on metallic stent frames to support the fabric. More recently, a polymer-based technology has been proposed as an alternative method to seal AAA. This review underlines the two platforms that are based on a polymer technology: 1) the polymer-filled endobags, so-called Endovascular Aneurysm Sealing (EVAS) with Nelix stent graft; and 2) the O-ring EVAR polymer-based proximal neck sealing device, so-called Ovation stent graft. Polymer characteristics for this particular aim, clinical applications, and durability results are summarized and commented critically. The platform that embraced the concept of inflating endobags filled with polymer to exclude the aneurysmal sac was not successful because of the lack of an adequate proximal fixation. The platform that used polymer to create a circumferential sealing of the aneurysmal neck has proven safe and effective.

Keywords: Endovascular Aneurysm Repair, EVAR, Aortic Aneurysm, PEG, polymer, Vascular Surgery, aortic endograft.

ABBREVIATION:

EVAR: Endovascular Aneurysm Repair

AAA: Abdominal Aortic Aneurysm

PTFE: polytetrafluoroethylene

SESGs: self-expanding stent grafts

PEG: Polyethylene Glycol

EL: Endoleak

EVAS: Endovascular Aneurysm Sealing

IFU: Instructions for Use

CE: Conformité Européenne

1. Introduction

Abdominal Aortic Aneurysm definition and treatment options

An abdominal aortic aneurysm (AAA) is a dilatation in the lower part of the major vessel that supplies blood to the body (aorta). The most accepted definition of AAA is based on the diameter of 3.0 cm or more, which usually is more than two standard deviations above the mean diameter for men. [1,2]

The AAA prevalence and incidence rates have decreased slightly over the last 20 years due to better risk factor management (i.e., cessation of smoking, hypertension, and diabetes treatment). In '90, the global prevalence in 75-79-year-olds was 2423 per 100,000 population versus 2275 in 2010. Nevertheless, AAA's natural history is a progressive growth till the rupture, which led to life-threatening bleeding. [3,4]

Depending on the aneurysm' size and how fast it's growing, treatment varies from watchful waiting to emergency surgery. To decrease AAA rupture incidence, treatment is typically recommended when the diameter is more than 5 cm. Over the last decades, the treatment options have changed. Traditional approach is represented by the open surgical repair: a longitudinal abdominal incision is performed; abdominal organs are eviscerated and aneurismectomy with subsequent aortic reconstruction. [5,6] In addition to this approach, a less invasive endovascular treatment has been proposed. Over the years, the so-called endovascular aneurysm repair (EVAR) has become the first treatment choice in patients with suitable anatomy. [7,8,9] EVAR represents a minimally invasive technique that has overcome some critical issues of open surgical repair such as higher intra- and peri-operative risk, the necessity of general anesthesia, intensive Care Unit stay, higher cardiac, pulmonary, and renal complications. These advantages led to a constant increasing in the AAA treatment feasibility especially in elderly patients with a substantial number of comorbidities which could be treated with reasonable perioperative risks [10] and good early and mid-term outcomes. [11,12]

Thirty years ago, Juan Parodi developed the first prototype of endograft for EVAR. It was a handmade device made of a tube-shaped aorto-aortic graft sutured at each end to a balloon-expandable stent based on the design of radiologist Julio Palmaz. This kind of device was implanted in a human body for the first time on September 7, 1990 in Buenos Aires, Argentina. [13] By 1994, the first commercially available devices were launched in the market. [14] Stent-graft material and design changed in various ways to improve conformability, reduce fracture, and minimize device migration rates.

For years, the basic design was based on metallic stent frames to support the fabric. More recently, a polymer-based technology has been proposed as an alternative method to seal AAA. This review underlines the two platforms that are based on polymer technology. Polymer characteristics for this particular aim, clinical applications, and durability results are summarized and commented critically.

2. REVIEW:

2.1 Concept of traditional Endovascular Aneurysm Repair

EVAR has gained wide acceptance as the preferred method to treat patients with AAA. [1] The standard endovascular procedure involves a stent-graft that is designed to exclude the aneurysm from the systemic circulation. (Figure 1) The stent is made of a metallic skeleton and covered with polytetrafluoroethylene (PTFE) or polyester fabric that keeps the stent impermeable. The device is advanced through the femoral artery using

fluoroscopic guidance toward the aneurysm site and then deployed. Sealing the proximal and distal ends of the aneurysm isolates the aneurysm, preventing subsequent rupture. Traditional EVAR devices employ self-expanding stent structures to promote graft-to-aortic wall apposition (seal) and fixation [15,16,17]. It is known that the amount of proximal device oversizing with self-expanding stent grafts (SESGs) influences neck progression over time. [18] In fact, once deployed, SESGs continue to expand until the nominal diameter is reached unless tissue resistance limits expansion. It has been reported that when aortic neck dilation occurs, it is related to adverse midterm outcomes [19,20].

Moreover, the “Achilles' heel” of EVAR is Endoleaks (EL), which consists in a persistent blood flow within the aneurysm sac. An EL is a relatively common complication of EVAR, and it could be detected intra-operatively (seen on the on-table angiogram after stent deployment), and during the follow-up. [21] Type I EL results from a failing proximal or distal sealing of the aneurysm by the stent graft. Although rare (1-5%), it is a potentially severe complication because a high-flow leakage pressurizes the sac. This condition deserves further treatment to prevent an aneurysm rupture. [22] Type II EL is commonly detected during the follow-up in 10–25% of EVAR patients. [23-24] It occurs from retrograde low-pressure collateral blood flow into the aneurysm sac, typically from a lumbar artery or the inferior mesenteric artery. Type II ELs can potentially enlarge and pressurize the aneurysm sac till the rupture, although this rarely happens. [25,26]

In summary, neck enlargement and type I and II EL represent the drawbacks of traditional EVAR devices, which have justified the research of different technology to seal the aneurysms based on polymers' use.

2.2 Polyethylene Glycol: a new tool for EVAR

The use of polymer is a fascinating field in endovascular techniques as an alternative to traditional SESGs. Two different stent graft designs combined with a polymer technology has been proposed for clinical application in the treatment of AAAs: 1) the polymer-filled endobags, so-called Endovascular Aneurysm Sealing (EVAS) with Nellix stent graft (Figure 2); and 2) the O-ring EVAR polymer-based proximal neck sealing device, so-called Ovation stent graft (Figure 3).

The polymer used in both platforms is the Polyethylene Glycol (PEG)-base one. PEG is a synthetic, non-biodegradable polymer widely used in the biomedical field, especially in tissue engineering research. [27,28,29] PEG is highly biocompatible but also biochemically inert and well suited for biological uses. Also, its non-immunogenicity and resistance to protein adsorption increase its applications. [30]

PEG-based polymers have a long history of use in medical products. Before approval, the polymer for EVAR passed the rigorous biocompatibility testing required by the international standard on biocompatibility (ISO 10993-1), and these results were reviewed to receive Conformité Européenne (CE) Mark and Food and Drug Administration (FDA) approval.⁸ In 2014, the 14-minute CustomSeal Fill Polymer Kit, which replaced the Ovation Fill Polymer Kit, received both CE and FDA approval

A significant amount of nonclinical testing was performed to evaluate the polymer kit [31]:

- Biocompatibility: comprehensive biocompatibility testing was performed per the EN ISO 10993-1:2009/ AC:2010 standard to evaluate the safety of the materials, including toxicity, sensitization, hemocompatibility, and irritation / intracutaneous reactivity (13-

week intramuscular implant). All test results confirm the products are biocompatible and safe for implanting in humans.

- Bench testing: extensive engineering testing was performed on the bench to evaluate the design characteristics in accordance with the EN ISO 25539-1:2009 cardiovascular implants—endovascular devices—part 1: endovascular prostheses. All test results confirmed that the products met their design specifications.

- Animal testing: chronic animal studies showed no evidence of structural changes in the fill polymer. A chronic animal study demonstrated no adverse effects associated with deliberate release of the fill polymer within the animals' vasculature. In Particular, no evidence of embolization, toxic response, or end-organ abnormality at 30 days was recorded.

These results were reviewed to receive CE Mark and FDA approval.

Over time, there have been two methods to use this polymer: the first technique uses the polymer as a filling material for the aneurysm sac (EVAS) (Figure 2A-B-C-E), while the second uses the polymer as a system for sealing and stabilizing the prosthesis at the level of the proximal aneurysmal neck (Ovation Endograft) (Figure 3A-B-C-D-E-F). The following paragraphs underline the clinical applications and the two stent graft designs' durability results with a polymer-based technology for AAA treatment.

2.3 The polymer-filled endobags, so-called Endovascular Aneurysm Sealing (EVAS) with Nellix stent graft.

The Nellix System (Endologix Inc., Irvine, CA, USA) for endovascular aneurysm sealing (EVAS) was introduced as a novel approach to the treatment of AAA [32] in 2013. The EVAS procedure is conceptually distinct from EVAR: the Nellix device is designed to seal and obliterate the aneurysm lumen and not to exclude it (Figure 2B-C).

The device consists of two balloon-expandable stents that support the aorta flow channel. The system is introduced into the aorta in a similar way to EVAR. By using guide-wires, the system is advanced into the aorta through the femoral arteries. The catheter sheaths are then pulled back, deploying the device with expands from the non-aneurysmal aorta proximally to the iliac arteries distally. The non-porous PTFE-based endobags are then filled with the biocompatible polyethylene glycol polymer (Figure 2B-C), which adjusts the endobag to fit the aneurysm sac lumen. Using bio-stable cross-linked polymer to inflate the endograft envelope in apposition to the aortic wall mimics the process of injection molding. It achieves high conformability, as the device is molded in-situ to the specific patient anatomy to accomplish a customized seal. Once this configuration is completed, the polymer cross-links to form a 'personalized' prosthesis.

Following CE marking in 2013, early reports suggested that EVAS may allow the treatment of complex aneurysms repair and may prevent type II endoleak formation [33]. In the first clinical reports by selected centers in a controlled setting of correct clinical indications and appropriate device implantation, [34,³⁵] the 30-day and 1-year outcomes of EVAS using the Nellix device were encouraging, and safety in the short term appeared to be established.

However, after more extensive use by many centers with more liberal indications to use the device in more challenging anatomical situations, the safety and durability of the procedure with Nellix became very controversial. Lately, more extended follow-up data showed a high rate of graft failure at two years and beyond. In 2016, the EVAS

FORWARD, an investigational device exemption trial, reported higher than expected rates of distal migration (6% incidence in a dedicated root-cause analysis), type IA endoleak, and aneurysm sac expansion, leading to a refinement of the instructions for use (IFU)³⁶. The new IFU suggested that EVAS would be most effective and durable in large AAA with minor thrombus and neck criteria similar to the IFU for another commercially available EVAR stent grafts.

In a retrospective analysis [37] of prospectively collected data of 295 cases of endovascular aneurysm sealing using the Nellix device for abdominal aortic aneurysm, therapeutic failure was seen at a surprising and alarming rate of 33.2%. The most common failure mechanism was the stent graft migration associated with type IA endoleak and sac expansion, as demonstrated by a recent systematic review. (Figure 4. A-B-C-D-E) [38] In many cases of failure, stent grafts were explanted from the patients' bodies with a significant open vascular intervention. EVAS failures were also responsible for AAA rupture with severe or fatal consequences for the patients. In case of graft explantation, surgeons noted that the bags containing polymer were still intact, the polymer was not leaking into the vasculature, and maintained the expected consistency. The cause of failure was reported to be the lack of a stable proximal fixation of the entire device into the aneurysm sac. [39,40,41]

Following the above-mentioned negative feedback on EVAS procedures' durability, the manufacturer voluntarily recalls the device, and the CE mark was suspended in 2019. [42]

In conclusion, a polymer filling the aneurysmal sac does not ensure the exclusion of the aneurysm because of the lack of proximal fixation. The real problem was in designing the stent grafts lacking proximal hooks or barbs to guarantee adequate fixation, rather than a failure of polymer technology by itself.

2.4 The O-ring EVAR polymer-based proximal neck sealing device, so-called Ovation stent graft

The first idea to use a polymer to seal the aortic neck by an endovascular operation was reported in 2007. The device with such technology was called Enovus (Trivascular, Boston Scientific, Santa Rosa, CA, USA). It was made of polymer-filled channels located along with the entire PTFE fabric of the endograft body. The endograft ring-shaped cavity was filled with radiopaque, three epoxy components that solidify, creating a rigid scaffold. This device was the first that used polymer with the distinct feature of substituting the endograft metallic stents, allowing radial and longitudinal support. The device was tested on an animal model [43] but did not receive the approval for clinical use on humans. Unfortunately, the clinical trials revealed some cases of fracture of the suprarenal stent. It was seen that the load created by anatomical flexing was concentrated across a small number of points, leading to a higher potential for fatigue. This problem was rapidly solved with a new design of more uniform strut width that achieves the goal of spreading stress-strain loads more evenly across the stent, thereby significantly improving the resistance to fatigue

Some years later, an evolution of the Enovus was proposed for human application with the name of Ovation Endograft (Endologix, Irvine, CA, USA). After successful animal investigations [44,45], the platform was tested in clinical trials with positive feedback. It represents a fundamental evolution in the use of polymers in the EVAR field. The endograft is based on a new concept design that separates fixation from sealing: fixation activity is assured by a suprarenal stent and anchors (not different from traditional suprarenal EVAR devices), while sealing activity is based on inflatable O-rings filled with a

low-viscosity, non-embolic, radiopaque fill polymer instead of traditional self-expanding stent grafts. The adaptability of the proximal O-ring filled with polymer to the patients' aortic neck anatomy determines a substantial increase in EVAR feasibility. In other words, polymer injected in the O-rings creates a customized circumferential sealing at the proximal aneurysmal neck level, with a further advantage of not executing any outward pressure on the aortic neck wall once the final deployment is completed. This assumption comes with a benefit in reducing aortic neck dilatation and consecutive endograft migration, a typical complication of SESGs. All these features define the revolutionary concept of "Custom Seal" as a tailored adaptation of polymer rings to the aortic wall, including wall calcification, wall thrombosis, and aortic tortuosity. [46,47,48]

Based on polymer channels rather than traditional metallic stent frames to support the fabric, the platform results in a lower profile of the delivery sheath, which is essential to bring the endograft from the groin to the abdominal aorta. The Ovation stent graft has a 14 Fr (4.66 mm) profile that is significantly lower than the 18-20 Fr (6-6.66 mm) profile of traditional SESGs. With such a low-profile delivery catheter, approximately 90% of men and 70% of women with AAA have access vessel diameters considered fit for endovascular repair. [49,50,51]

In the beginning, the innovation of using a polymer at the level of the proximal neck raised some worries regarding the correct sealing of the aortic neck over time, the eventual aortic neck evolution, stability and durability of polymer, and the possibility of polymer leakage with a consecutive harmful complication for the patients.

All these concerns disappeared when large patient populations treated with this kind of polymer technology became available. The ENCORE database enrolled more than 1200 patients undergoing EVAR with Ovation endograft with 50% of cases defined as complex anatomy (neck length <10 mm, neck diameter >28 mm, neck angle >60°, reverse neck taper >10%, distal common iliac artery diameter <10 mm, or external iliac artery diameter <6 mm). Technical success was reached in 99.7%, highlighting the good endograft ability to conform to difficult anatomies [52], data subsequently confirmed by several studies.⁵³

The importance of polymer in the proximal endograft zone is even greater in the exploratory experience of the use of the Ovation endograft in the treatment of patients with Juxtarenal-AAA (those aneurysms that involve the infrarenal abdominal aorta adjacent to or including the lower margin of renal artery origins [54]) and unfit for traditional open surgery repair of Fenestrated-EVAR. In these particular cases, the endograft is deployed, making the sealing ring landing very close to the lowermost renal artery. (Figure 3A-E-F) [55-56]. The correct deployment assures the stability of this implant of the endograft, and, in particular, by the sealing activity of polymer rings, including the O-ring capability to adapt to irregular anatomies.

The durability of the O-ring EVAR polymer-based devices is due also to the minimum oversize (10-15%) at the proximal seal zone, as opposed to traditional self-expanding stents, which generally require to be oversized by 20% to 30% to ensure apposition of the stent graft to the aortic wall. This rate of oversizing leads to continuous outward radial force being applied to the aneurysm neck. [57,58,59] A meta-analysis of neck dilation after EVAR, patients with neck dilation were more likely to develop type IA endoleak (persistent filling of the AAA due to incomplete seal or ineffective seal at the proximal end of the stent graft), experience graft migration, or undergo reintervention [60]

In a recent analysis of patients treated with the O-ring EVAR polymer-based proximal neck sealing platform, at a minimum follow-up CT scan of 24 months, neither aortic neck dilation nor stent graft migration occurred. [18] This finding may suggest that

aortic neck evolution could not be associated with EVAR at midterm follow-up when an endograft with no chronic outward radial force is implanted.

The potential dark side of this polymer-based endograft is the polymer leakage outside the fill channels. The polymer's system exposure has been reported as a rare complication, responsible for hypersensitivity reaction and anaphylactic shock. [61,62,63]

While the Ovation device's unique sealing mechanism affords a lower profile and improved sealing ability, patient safety was a primary driver during the stent graft development. As part of the process for approval by regulatory agencies worldwide, the Ovation System's polyethylene glycol (PEG)-based polymer was chosen because it is non-thrombogenic and biocompatible; it was designed to be soluble and non-embolic if spilled accidentally into the vasculature after mixing.

In early 2012, a caution statement was approved for the Ovation fill polymer and included in the Instructions for Use (IFU); it warned against balloon dilation of the sealing rings within 20 minutes of mixing the polymer to avoid potential damage to or compromise of the sealing rings. At the same time, the IFU were also updated to include instructions to manage patients who experience a hypersensitivity reaction to the device materials in accordance with standard recommendations for treatment of patients with radio-contrast allergies (e.g., antihistamines, corticosteroids, and adrenaline). [64]

Gupta N. and colleagues reviewed all reports related to polymer leaks with the device received by the manufacturer. The polymer leak was reported in 26 patients over more than 10,000 endograft implants. Factors that appear to contribute to the risk of polymer leak include the initial manufacturing process for the device, excessive graft manipulation, early ballooning before complete polymer cure, and lower body temperature, which can slow the polymer cure rate. [65]

3. CONCLUSION:

Polymer-based technology has been proposed as alternative methods to treat AAA with an endovascular approach. Two different polymer-based platforms have been developed for clinical purposes. The platform that embraced the concept of inflating endobags filled with polymer combined with stents to exclude the aneurysmal sac was not successful because of the lack of an adequate proximal fixation of the device. The polymer per se was not responsible for the failure of this platform. The manufacturer recalled the device from the market. Some prototypes are now testing the efficacy of endobags filled with polymer combined with stents equipped with barbs for adequate proximal fixation. The platform that used polymer to create a circumferential sealing of the aneurysmal has proven safe and effective. However, some rare cases of polymer spill over into the human vasculature may generate systemic reactions requiring careful clinical monitoring and treatment. By adapting the O-ring to the aortic wall, this polymer-based platform offers a customized sealing of the aneurysm, which remain stable over the years without influencing neck dilatation. Finally, the low profile of such a platform based on polymer channels rather than traditional metallic stent frames to support the fabric may expand patient applicability for a mini-invasive EVAR treatment. Further application of polymer-based technology is expected in the next year to treat other vascular diseases as thoracic and thoracoabdominal aortic aneurysms and thoracic dissections.

Figures:

Figure 1. Traditional stent-graft design. A) Picture of the endograft deployed in Abdominal Aortic Aneurysm. Traditional EVAR devices employ self-expanding stent structures to promote graft-to-aortic wall apposition (seal) and fixation. B) Intraoperative fluoroscopic image of the endograft deployed in the AAA. C) Angiographic acquisition that reveals a good exclusion of the AAA and the good patency of the endograft. D) 3D volume rendering of Computed Tomography Angiography at 1-month follow-up that shows the correct aneurysm exclusion.

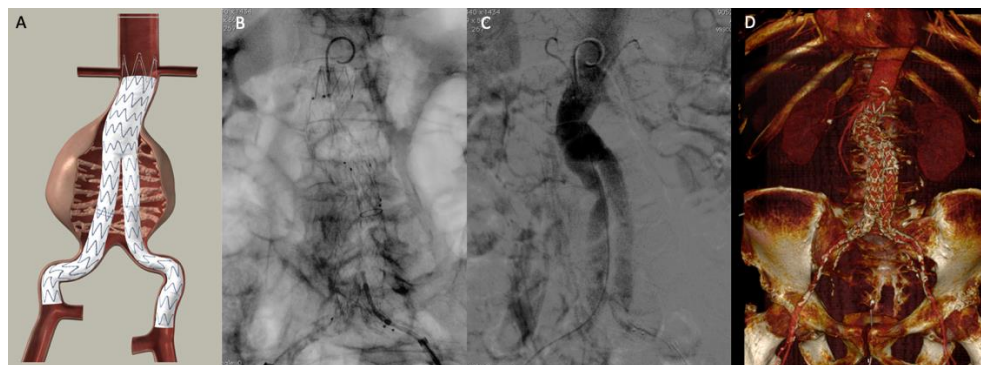


Figure 2. Nellix stent graft. A-B) Picture of Nellix endograft during the endobags' polymer filling manoeuvres. The asterisk (*) indicates the endobags that adapt to the morphology of the entire aneurysm sac. C) Axial Computed Tomography Angiography detail of a Nellix endograft implanted. The stent grafts (arrows) are located in the middle of endobags, which are filled with polymer (*). D) Intraoperative image of the Nellix stent graft deployed with angiographic contrast medium that highlights the good patency of the endograft and the exclusion of AAA. E) 3D volume rendering of Computed Tomography Angiography at 3-months follow-up post-implantation that reveals a good aneurysm exclusion. The asterisk (*) indicate the polymer-filled endobags.

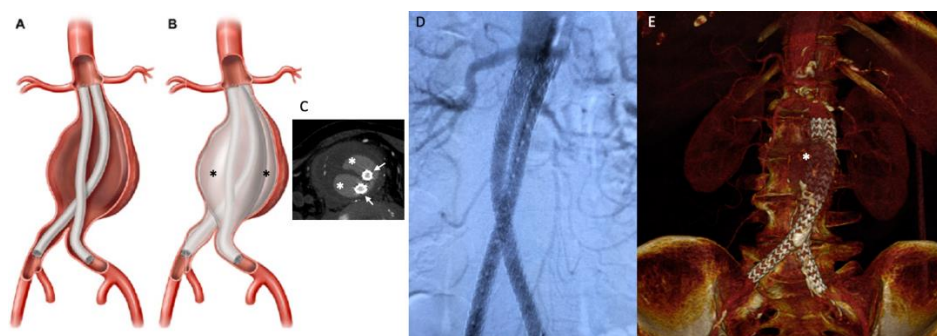
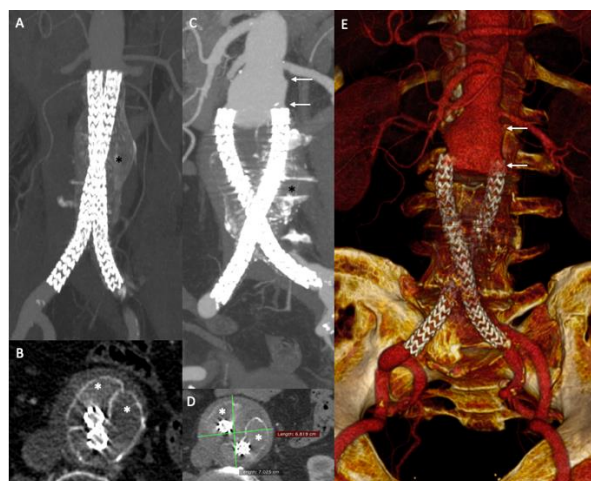


Figure 3. Ovation stent graft. A) Picture of the Ovation endograft. Proximal sealing is assured by polymer filled O-rings (red circle) adapted to the aortic neck anatomy. B-C) Details of the axial appearance of O-rings well-apposed to the aortic wall. D) Intraoperative image of the Ovation stent graft deployed. The asterisk (*) highlights the polymer filled O-rings. E) Angiographic acquisition that reveals the good exclusion of the AAA by the polymer filled O-rings (*). F) 3D volume rendering of Computed Tomography Angiography at 3-months follow-up that shows the correct exclusion of the AAA. The asterisk (*) indicates the polymer filled O-rings located in the proximal fixation zone.

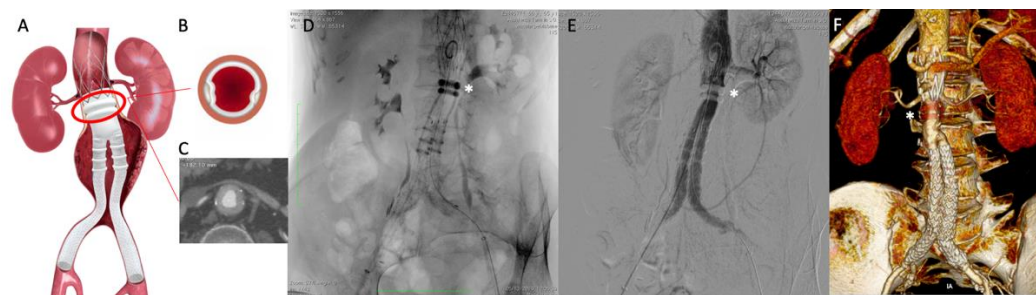

Figure 4. Case of Nellix Endograft Failure due to distal migration. A) Computed Tomography Angiography detail of a Nellix endograft implantation. The asterisk (*) indicates the polymer filled endobags that correctly seal the aneurysm sac. B) Axial view of the same exam highlights the correct stents' and endobags' configuration, asterisks (*) mark the two endobags adapted to the aneurysm sac. C) Computed Tomography Angiography detail of the 2-year follow-up exam revealing a distal migration of the entire system (arrows) with AAA enlargement (D) and endobags dislocation (*). E) 3D volume rendering of Computed Tomography Angiography of the endograft migration and failure, requiring open surgical conversion.



Author Contributions: Conceptualization: GdD, GP; Methodology: GdD, GP, GG, DB; Investigation, GdD; EP, CP, BB, GG; Writing – Original Draft Preparation: GdD, EP, CP, GG, BB; Writing – Review & Editing: GdD, EP, CP, GG, DB, BB, GG, GP; Supervision: GdD, GP

Funding: This research received no external funding

Conflicts of Interest: The authors declare no conflict of interest

4. REFERENCES:

1. Wanhainen A, Verzini F, Van Herzele I, Allaire E, Bown M, Cohnert T, et al. Editor's Choice - European Society for Vascular Surgery (ESVS) 2019 Clinical Practice Guidelines on the Management of Abdominal Aorto-iliac Artery Aneurysms. *Eur J Vasc Endovasc Surg*. 2019 Jan;57(1):8-93. doi: 10.1016/j.ejvs.2018.09.020. Epub 2018 Dec 5. Erratum in: *Eur J Vasc Endovasc Surg*. 2020 Mar;59(3):494.
2. Thompson SG, Bown MJ, Glover MJ, Jones E, Masconi KL, Michaels JA, et al. Screening women aged 65 years or over for abdominal aortic aneurysm: a modelling study and health economic evaluation. *Health Technol Assess*. 2018;22(43):1-142.
3. Oliver-Williams C, Sweeting MJ, Turton G, Parkin D, Cooper D, Rodd C, et al. Lessons learned about prevalence and growth rates of abdominal aortic aneurysms from a 25-year ultrasound population screening programme. *Br J Surg* 2018;105:68e74.

4. Schmitz-Rixen T, Keese M, Hakimi M, Peters A, Böckler D, Nelson K, et al. Ruptured abdominal aortic aneurysm-epidemiology, predisposing factors, and biology. *Langenbecks Arch Surg.* 2016;401(3):275-88.
5. Davidovic LB, Maksic M, Koncar I, Ilic N, Dragas M, Fatic N, et al.. Open Repair of AAA in a High Volume Center. *World J Surg.* 2017;41(3):884-891.
6. Williams CR, Brooke BS. Effectiveness of open versus endovascular abdominal aortic aneurysm repair in population settings: A systematic review of statewide databases. *Surgery.* 2017;162(4):707-720.
7. Suckow BD, Goodney PP, Columbo JA, Kang R, Stone DH, Sedrakyan A, et al. National trends in open surgical, endovascular, and branched-fenestrated endovascular aortic aneurysm repair in Medicare patients. *J Vasc Surg.* 2018;67(6):1690-1697.e1.
8. Bacharach JM, Wood EA, Slovut DP. Management of Aortic Aneurysms: Is Surgery of Historic Interest Only? *Curr Cardiol Rep.* 2015;17(11):105.
9. Setacci C, de Donato G, Setacci F. Endografts for the treatment of aortic infection. *Semin Vasc Surg.* 2011;24(4):242-9.
10. Han Y, Zhang S, Zhang J, Ji C, Eckstein HH. Outcomes of Endovascular Abdominal Aortic Aneurysm Repair in Octogenarians: Meta-analysis and Systematic Review. *Eur J Vasc Endovasc Surg.* 2017;54(4):454-463.
11. Pasqui E, de Donato G, Giannace G, Panzano C, Setacci C, Palasciano G. Management of abdominal aortic aneurysm in nonagenarians: A single-centre experience. *Vascular.* 2020 Jul 1:1708538120936831.
12. Sonesson B, Dias N, Resch T. Is there an age limit for abdominal aortic aneurysm repair? *J Cardiovasc Surg (Torino).* 2018;59(2):190-194.
13. Veith FJ, Marin ML, Cynamon J, Schonholz C, Parodi J. 1992: Parodi, Montefiore, and the first abdominal aortic aneurysm stent graft in the United States. *Ann Vasc Surg.* 2005;19(5):749-51.
14. Ivancev K, Vogelzang R. A 35 Year History of Stent Grafting, and How EVAR Conquered the World. *Eur J Vasc Endovasc Surg.* 2020;59(5):685-694.
15. Setacci F, Sirignano P, de Donato G, Chisci E, Iacoponi F, Galzerano G, et al. AAA with a challenging neck: early outcomes using the Endurant stent-graft system. *Eur J Vasc Endovasc Surg.* 2012;44:274-9.
16. Zandvoort HJ, Gonçalves FB, Verhagen HJ, Werson DA, Moll FL, de Vries JP, et al. Results of endovascular repair of infrarenal aortic aneurysms using the Endurant stent graft. *J Vasc Surg.* 2014;59(5):1195-202.
17. Deery SE, Shean KE, Pothof AB, O'Donnell TFX, Dalebout BA, Darling JD, et al. Three-Year Results of the Endurant Stent Graft System Post Approval Study. *Ann Vasc Surg.* 2018;50:202-208.
18. de Donato G, Setacci F, Bresadola L, Castelli P, Chiesa R, Mangialardi N et al. Aortic neck evolution after endovascular repair with Tri-Vascular Ovation stent graft. *J Vasc Surg.* 2016;63:8-15.
19. Cao P, Verzini F, Parlani G, Rango PD, Parente B, Giordano G, et al. Predictive factors and clinical consequences of proximal aortic neck dilatation in 230 patients undergoing abdominal aorta aneurysm repair with self-expandable stent-grafts. *J Vasc Surg* 2003;37:1200-5.
20. Dillavou ED, Muluk S, Makaroun MS. Is neck dilatation after endovascular aneurysm repair graft dependent? Results of 4 US Phase II trials. *Vasc Endovasc Surg.* 2005;39:47-54.
21. Cannavale A, Lucatelli P, Corona M, Nardis P, Cannavale G, De Rubeis G, et al. Current assessment and management of endoleaks after advanced EVAR: new devices, new endoleaks? *Expert Rev Cardiovasc Ther.* 2020;18(8):465-473.
22. Spanos K, Rohlfs F, Panuccio G, Eleshra A, Tsilimparis N, Kölbel T. Outcomes of endovascular treatment of endoleak type Ia after EVAR: a systematic review of the literature. *J Cardiovasc Surg (Torino).* 2019;60(2):175-185.
23. White SB, Stavropoulos SW. Management of Endoleaks following Endovascular Aneurysm Repair. *Semin Intervent Radiol.* 2009;26:33-38.
24. Quinn AA, Mehta M, Teymouri MJ, Keenan ME, Paty PSK, Zhou Y, et al. The incidence and fate of endoleaks vary between ruptured and elective endovascular abdominal aortic aneurysm repair. *J Vasc Surg.* 2017;65(6):1617-1624.
25. Steinmetz E, Rubin BG, Sanchez LA, Choi ET, Geraghty PJ, Baty J, et al. Type II endoleak after endovascular abdominal aortic aneurysm repair: a conservative approach with selective intervention is safe and cost-effective. *J Vasc Surg.* 2004;39(2):306-13.
26. Gonzalez-Urquijo M, Lozano-Balderas G, Fabiani MA. Type II Endoleaks After EVAR: A Literature Review of Current Concepts. *Vasc Endovascular Surg.* 2020;54(8):718-724.

27. D'souza AA, Shegokar R. Polyethylene glycol (PEG): a versatile polymer for pharmaceutical applications. *Expert Opin Drug Deliv.* 2016;13(9):1257-75.
28. Putti M, Mes T, Huang J, Bosman AW, Dankers PYW. Multi-component supramolecular fibers with elastomeric properties and controlled drug release. *Biomater Sci.* 2019;8(1):163-173.
29. Wang JZ, You ML, Ding ZQ, Ye WB. A review of emerging bone tissue engineering via PEG conjugated biodegradable amphiphilic copolymers. *Mater Sci Eng C Mater Biol Appl.* 2019;97:1021-1035.
30. Liu SQ, Tay R, Khan M, Rachel Ee PL, Hedrick JL, Yang YY. Synthetic hydrogels for controlled stem cell differentiation. *Soft Matter.* 2010;6(1):67-81.
31. US Food and Drug Administration. TriVascular, Inc. Ovation abdominal stent graft system. Summary of Safety and Effectiveness Data (SSED). http://www.accessdata.fda.gov/cdrh_docs/pdf12/P120006b.pdf. Accessed May 9, 2015.
32. Choo XY, Hajibandeh S, Hajibandeh S, Antoniou GA. The Nellix endovascular aneurysm sealing system: current perspectives. *Med Devices (Auckl).* 2019;12:65-79.
33. Karthikesalingam A, Cobb RJ, Khoury A, Choke EC, Sayers RD, Holt PJ, et al. The morphological applicability of a novel endovascular aneurysm sealing (EVAS) system (Nellix) in patients with abdominal aortic aneurysms. *Eur J Vasc Endovasc Surg* 2013;46:440-5.
34. Böckler D, Holden A, Thompson M, Hayes P, Krievins D, de Vries JP, et al. Multicenter Nellix EndoVascular Aneurysm Sealing system experience in aneurysm sac sealing. *J Vasc Surg.* 2015;62:290-8.
35. Silingardi R, Coppi G, Ferrero E, Lauricella A, Psacharopulo D, Saitta G, et al. Midterm Outcomes of the Nellix Endovascular Aneurysm Sealing System: A Dual-Center Experience. *J Endovasc Ther.* 2016;23(5):695-700.
36. Carpenter JP, Lane JS 3rd, Trani J, Hussain S, Healey C, Buckley CJ, et al. Refinement of anatomic indications for the Nellix System for endovascular aneurysm sealing based on 2-year outcomes from the EVAS FORWARD IDE trial. *J Vasc Surg* 2018; 68:720-30.
37. Stenson KM, de Bruin JL, Loftus IM, Holt PJE. Migration and sac expansion as modes of midterm therapeutic failure after endovascular aneurysm sealing. *J Vasc Surg.* 2020;71: 457-469.
38. Choo XY, Hajibandeh S, Hajibandeh S, Antoniou GA. The Nellix endovascular aneurysm sealing system: current perspectives. *Med Devices (Auckl).* 2019 Feb 19; 12:65-79.
39. Singh AA, Benaragama KS, Pope T, Coughlin PA, Winterbottom AP, Harrison SC, et al. Progressive Device Failure at Long Term Follow Up of the Nellix EndoVascular Aneurysm Sealing (EVAS) System. *Eur J Vasc Endovasc Surg.* 2021;61(2):211-218.
40. Zoethout AC, Zerwes S, Zeebregts CJAM, Heyligers JMM, De Vries JPJM, Oberhuber A, et al. Preliminary outcome of Nellix-in-Nellix extensions in patients treated with failed endovascular aneurysm sealing. *J Vasc Surg.* 2019;70(4):1099-1106.
41. Harrison SC, Winterbottom AJ, Coughlin PA, Hayes PD, Boyle JR. Editor's Choice - Mid-term Migration and Device Failure Following Endovascular Aneurysm Sealing with the Nellix Stent Graft System - a Single Centre Experience. *Eur J Vasc Endovasc Surg.* 2018;56(3):342-348.
42. Endologix provides an update on the previously announced voluntary Nellix System recall. Available at: <https://endologix.com/wp-content/uploads/2019/01/2019.01.22-Press-ReleaseNellix-CE-Mark-FINAL.pdf>. Accessed January 2021.
43. Hynesek RL, Sadek M, Derubertis BG, Ryer EJ, Choi J, Hsu S, et al. Evaluation of pressure transmission and intra-aneurysmal contents after endovascular repair using the Trivascular Enovus expanded polytetrafluoroethylene stent graft in a canine model of abdominal aortic aneurysm. *J Vasc Surg.* 2007;46:1005-13.
44. Hynesek RL, Sadek M, Derubertis BG, Ryer EJ, Choi J, Hsu S, et al. Evaluation of pressure transmission and intra-aneurysmal contents after endovascular repair using the Trivascular Enovus expanded polytetrafluoroethylene stent graft in a canine model of abdominal aortic aneurysm. *J Vasc Surg.* 2007;46(5):1005-13.
45. Faries PL, Dayal R, Rhee J, Trocciola S, Kent KC. Stent graft treatment for abdominal aortic aneurysm repair: recent developments in therapy. *Curr Opin Cardiol.* 2004;19(6):551-7.
46. de Donato G, Setacci F, Sirignano P, Galzerano G, Borrelli MP, di Marzo L, et al. Ultra-low profile Ovation device: is it the definitive solution for EVAR? *J Cardiovasc Surg (Torino).* 2014;55:33-40.

47. Georgakarakos E, Ioannou CV, Georgiadis GS, Storck M, Trellopoulos G, Koutsias S, et al. The ovation abdominal stent graft for the treatment of abdominal aortic aneurysms: current evidence and future perspectives. *Expert Rev Med Devices*. 2016;13(3):253-62.
48. Georgakarakos E, Papatheodorou N, Argyriou C, Tasopoulou KM, Doukas D, Georgiadis GS. An update on the ovation abdominal stent graft for the treatment of abdominal aortic aneurysms: current evidence and future perspectives. *Expert Rev Med Devices*. 2020;17(12):1249-1256.
49. Sweet MP, Fillinger MF, Morrison TM, Abel D. The influence of gender and aortic aneurysm size on eligibility for endovascular abdominal aortic aneurysm repair. *J Vasc Surg*. 2011;54:931-937.
50. Mehta M, Valdés FE, Nolte T, Mishkel GJ, Jordan WD, Gray B, et al; A Pivotal Clinical Study to Evaluate the Safety and Effectiveness of the Ovation Abdominal Stent Graft System Investigators. One-year outcomes from an international study of the Ovation Abdominal Stent Graft System for endovascular aneurysm repair. *J Vasc Surg*. 2014;59:65-73.e1-3.
51. Varkevisser RRB, Swerdlow NJ, Verhagen HJM, Lyden SP, Schermerhorn ML. Similar 5-year outcomes between female and male patients undergoing elective endovascular abdominal aortic aneurysm repair with the Ovation stent graft. *J Vasc Surg*. 2020 Jul;72:114-121.
52. Swerdlow NJ, Lyden SP, Verhagen HJM, Schermerhorn ML. Five-year results of endovascular abdominal aortic aneurysm repair with the Ovation abdominal stent graft. *J Vasc Surg*. 2020;71:1528-1537.e2.
53. de Donato G, Setacci F, Bresadola L, Castelli P, Chiesa R, Mangialardi N, et al. Midterm Results of Proximal Aneurysm Sealing With the Ovation Stent-Graft According to On- vs Off-Label Use. *J Endovasc Ther*. 2017;24(2):191-197.
54. Crawford ES, Beckett WC, Greer MS. Juxtarenal infrarenal abdominal aortic aneurysm. Special diagnostic and therapeutic considerations. *Ann Surg*. 1986;203:661-70.
55. de Donato G, Pasqui E, Mele M, Panzano C, Giannace G, Setacci F, et al. The use of a low-profile stent graft with a polymer ring sealing technology combined with bare renal stent (vent technique) in patients with juxtarenal aneurysm not eligible for open surgery and fenestrated endograft. *J Vasc Surg*. 2020;71:1843-1850.
56. Volpe P, Alberti A, Massara M. Endovascular Treatment of Juxtarenal Abdominal Aortic Aneurysms Recurring to the "Vent Technique". *Ann Vasc Surg*. 2020;68:270-274.
57. Kret MR, Tran K, Lee JT. Change in Aortic Neck Diameter after Endovascular Aortic Aneurysm Repair. *Ann Vasc Surg*. 2017;43:115-120.
58. Tassiopoulos AK, Monastiriotis S, Jordan WD, Muhs BE, Ouriel K, De Vries JP. Predictors of early aortic neck dilatation after endovascular aneurysm repair with EndoAnchors. *J Vasc Surg*. 2017;66(1):45-52.
59. Ribner AS, Tassiopoulos AK. Postoperative Aortic Neck Dilation: Myth or Fact? *Int J Angiol*. 2018;27(2):110-113.
60. Kouvelos GN, Oikonomou K, Antoniou GA, Verhoeven EL, Katsargyris A. A systematic review of proximal neck dilatation after endovascular repair for abdominal aortic aneurysm. *J Endovasc Ther*. 2017;24:59-67.
61. Siani A, Accrocca F, De Vivo G, Mounayergi F, Siani LM, Antonelli R. Anaphylactic Reaction during Implantation of Ovation Abdominal Stent Graft in Patients with Abdominal Aortic Aneurysm. *Ann Vasc Surg*. 2017;39:289.e1-289.e4.
62. Sfyroeras GS, Moulakakis KG, Antonopoulos CN, Manikis D, Vasdekis SN. Anaphylactic Reaction During Implantation of the Ovation Stent-Graft System in a Patient With Abdominal Aortic Aneurysm. *J Endovasc Ther*. 2015;22(4):620-2.
63. Simonte G, Isernia G, Fiorucci B, Paciaroni E, Cieri E, Rebonato A, et al. Polymer Embolization and Anaphylactic Reaction during Implantation of an Ovation Stent Graft for Abdominal Aortic Aneurysm Exclusion. *Ann Vasc Surg*. 2018;50:298.e7-298.e11.
64. Macy EM. Current Epidemiology and Management of Radiocontrast-Associated Acute- and Delayed-Onset Hypersensitivity: A Review of the Literature. *Perm J*. 2018;22:17-072.
65. Gupta N, Hynes KL, Mahrouyan O, Briggs CS, Azzizadeh A. Polymer leak with the Ovation Abdominal Stent Graft System: Early recognition and treatment. *Vascular*. 2020;28:159-164.