

# Preliminary evaluation of cannabidiol use in an Asian elephant: brief report

## Authors

MVZ Flor C. Ortiz<sup>1,2</sup>, MVZ Mish Castillo<sup>\*1,2</sup>, M en MVZ Quetzalli Hernández, pMVZ Carlos Flores

<sup>1</sup> Red Cannabis Medicinal Veterinaria, <sup>2</sup> ICAN Vets, Mexico City, \* Corresponding Author: [mish@ican.mx](mailto:mish@ican.mx)

## Abstract

The Asian elephant (*Elephas maximus*) is one of the largest herbivore mammals in the world. A portion of the total elephant population is under human care, where health problems such as skin lesions and decreased appetite are reported. The objective of this study was to apply the therapeutic properties of cannabidiol (CBD) to aid treatment of palmar abscesses and a suboptimal food intake in a female Asian elephant in Mexico. A CBD-isolate compounded medication was administered orally at a dose of 0.05 mg/kg/day. CBD administration showed positive effects such as reduction in abscess size, decreased food selectivity, increased food intake, weight gain and increased mobility. More research in elephants is needed to understand their cannabinoid pharmacodynamics and pharmacokinetics and proposing a dosage range and therapeutic applications for this species.

**Keywords:** Asian elephant, *Elephas maximus*, cannabidiol, cannabis, CBD, endocannabinoid system

## Introduction

The Asian elephant (*Elephas maximus*) is one of the largest herbivore mammals in the world (Fowler & Mikota, 2006). In 2019, a total elephant population was estimated at 50,000: 30,000 living in the wild plus around 16,000 under human care (Kumar et al., 2019).

Miller et al., mention that frequent causes of morbidity in wild Asian elephants are lesions, gastrointestinal ailments, endo- and ectoparasites; while those for elephants under human care were reported to be abscesses, cancer, non-parasitic infectious diseases, renal illnesses, reproductive problems, skin pathologies, stereotyped behavior, pathologies of the incisors, and ventral edema (Miller et al., 2015). Other problems usually presented by elephants under human care are those related to nutrient-deficient diets or monotonous pastures, causing significant selectivity since their free-ranging feeding habits vary according to food availability. This translates into decreased appetite and low body weight, usually predisposing to other health problems (Kumar et al., 2019).

The endocannabinoid system (ECS) is an intercellular communication system in charge of regulating physiological processes in the organism and promoting homeostasis. It is composed of cannabinoid receptors (CB1 and CB2) found on cellular membranes, their endogenous ligands (known as endocannabinoids) and the enzymes required for their synthesis and degradation. This system can be found in all vertebrates, as well as some primitive organisms in the Cnidaria phylum such as *Hydra vulgaris* (de Petrocellis et al., 2004; Silver, 2019).

The cannabis plant (*Cannabis sativa* L.) belongs to the Cannabaceae family. It produces numerous chemical compounds, including phytocannabinoids (such as tetrahydrocannabinol or THC and cannabidiol or CBD), terpenes, flavonoids, and phenolic acids (Andre et al., 2016). These substances have anti-inflammatory, anticancer, and neuroprotective effects, among others (Russo & Marcu, 2017). Phytocannabinoids interact with cannabinoid receptors and generate their pharmacological effects on the organism (Hazzah et al., 2020; Patil et al., 2020).

Several decades of research on the endocannabinoid system already exist, backing up the beneficial properties of phytocannabinoids and their low incidence of adverse effect in several species. This is the basis for this preliminary evaluation using an active ingredient found in cannabis as a medication for an Asian elephant under human care.

Until March 2021, the only other report mentioning the use of cannabinoid in elephants is a news coverage of the Warsaw Zoo from August 2020 mentioning they would evaluate the effects of CBD on the mood of their elephants (Nevett, 2020). Up to date there is no more information available regarding that study, which would make this the first report described in literature regarding the use of CBD as a complementary treatment in the veterinary care of elephants.

## Case Presentation

The patient is a female Asian elephant (*Elephas maximus*) kept under human care, approximately 55 years old; she is currently living in a wildlife conservation park in Mexico, where she has been living since 2009.

During the initial clinical examination, the patient was found to be alert and responsive, with a body condition score of 2.5/5, weighing 4,624 kg (10,194 lbs) on September 23, 2020. The elephant presented several ailments: a) Abscesses compromising the palmar and plantar aspects of fore- and hindlimbs, as well as some nails of the forelimbs, specifically, two abscesses in nails 4 and 5 of the right forelimb (RFL) (images 1 and 2); b) Decreased appetite and excessive food selectivity; c) Decreased locomotion and exploration behaviors, related to the abscesses in hands and feet.

## Prior Clinical History

The elephant has shown a predisposition to suffer from abscesses in nails, palms of the hands, and occasionally soles of the feet, presenting with five (5) to eight (8) abscesses per year since her arrival at the park in 2009. The most chronic abscess the patient presented at the time of the start of this study appeared in the cuticle of the fifth nail of the RFL between December 2019 and January 2020. This abscess further complicated months later by compromising all of the cuticle, the entire nail, and part of the palm. The abscess in nail 4 of the RFL appeared in April 2020. Both abscesses receive a daily **routine treatment** which consists of removing detritus and dirt (mud, pebbles, etc.) with drinking water, and a brushing with baby shampoo, followed by a cleaning and disinfection alternating one of the following: chlorhexidine at 0.5% (25 mL Nolvasan® solution diluted in 75 mL of drinking water), benzalkonium chloride at 0.25% (Antibenzil® tincture, undiluted), or iodine foam dressing at 1.1% (Germisin®, undiluted).

## Daily Food Ration

In the mornings, the elephant receives half a bale of oat hay (averaging 17.5 kg) and 1.5 kg of alfalfa inside her enclosure to encourage her to leave her night house. During her time in her enclosure she receives another half a bale distributed during the day (averaging 17.5 kg). In the afternoons she is given 1.33 bales of oat hay (47 kg average) and 1.5 kg of alfalfa, in addition to Omolin® concentrate, approximately 12.5 kg, and 2.5 kg of oats.

Her training ration is 15 kg of assorted fruits plus an average of 3 kg of watermelon or melon per day. Additionally, she is provided with food environmental enrichment one to three times a week, using one of the following: palm leaves, corn leaves, bamboo leaves or fresh reeds.

## Treatment with Cannabidiol

ICAN Vets and the Veterinary Medical Cannabis Network Mexico collaborated with the veterinary team at the conservation park to provide counsel regarding the formulation and prescription of a magistral formula (also known as drug compounding) based on isolated CBD to provide treatment for the elephant patient. The objective was to evaluate the medical benefits that this cannabinoid could provide for the patient's aforementioned ailments, as well as determining the incidence of any adverse effects.

The dosage was calculated by extrapolating doses already in use for horses, since the veterinary team uses equine doses of other analgesic treatments with NSAIDS for these elephants. Luedke recommends 250 mg CBD per animal every 12 or 24 hours (Luedke, 2020); Ellis & Contino used 250 mg/animal every 12 h (Ellis & Contino, 2019). Due to financial constraints, it was decided to dose 225 mg total every 24 hours (approximately 0.05 mg/kg per day).

The treatment took place for eight weeks, from 28 November 2020 to 31 January 2021, with a five-day suspension from January 3 to January 8 due to the medication running out and delays with the delivery of the second bottle due to the pandemic restrictions.

The elephant has already been trained using protected handling, so she knows how to open her mouth on command and allows depositing the medication in the oral cavity behind the tongue after which she receives a chunk of fruit, so she swallows the medication together with the fruit (images 3 and 4).

The titration process was started on November 28, this means a gradual increase in CBD dosing to minimize the incidence of adverse effects. A magistral formula or compounded drug was used, Botican® brand, containing 9000 mg of CBD isolate in grapeseed oil, for a total of 9000 mg in 40 mL (concentration: 225 mg of CBD per milliliter) for oral administration. The first day, the patient was administered a dose of 56.25 mg de CBD (0.25 mL); the second day the dose was 112.5 mg (0.5 mL); the third day with a dose of 168.75 mg (0.75 mL), and the fourth day the total dose of 225 mg (1 mL) was administered. In addition to the CBD, the elephant continued receiving the routine treatment for her abscesses.

## Results and follow-up

For each of the ailments mentioned above, the following changes were observed: a) The abscesses in nails and palms decreased their size (images 5 to 8), finding a significant improvement since the CBD was added to the aforementioned routine treatment. b) The decreased appetite and food selectivity stopped by day three of CBD administration, still during the titration phase and before reaching the total dose. The improvement in appetite was the first and most evident change: the elephant had had periods where she only ate a 30% offer ration; if she did not like her food she would just play with it instead of eating it. Her food intake during October was about 60 to 70% of her daily ration and in November it hovered around a 65-75%. With the CBD treatment, her food intake starting in December was estimated to be around 90% of her daily ration. This decrease in food selectivity and increased food intake resulted in a weight gain of 252 kg in only five weeks (table 1). Unfortunately, the patient's appetite decreased after the CBD medication was suspended. c) Locomotion within her enclosure increased since the CBD administration, resulting in a greater and more homogeneous wear down of her palms and soles.

Table 1. Weights recorded for the female Asian elephant patient.

| WEIGHT DATE  | WEIGHT (kg) | VARIATION                                     |
|--|-------------|---|
| JUNE   | 4,505       | -   |
| JULY   | 4,615       | gained 110 kg                                 |
| AUGUST   | 4,530       | lost 85 kg                                    |
| 23-Sep-2020  | 4,624       | gained 94 kg                                  |
| There are no reliable records for October or November.<br>CBD administration started on 28-Nov-2020. |             |   |
| 11-Dec-2020  | 4,643       | gained 19 kg                                  |
| 06-Jan-2021  | 4,895       | <b>gained 252 kg<br/>after 5 weeks on CBD</b> |

Furthermore, there were incidental findings such as changes in the animal's behavior. When coming out of her night house, the elephant took several minutes coming out, this time decreased during her treatment with CBD. Additionally, she had not visited the drinking fountain area of her enclosure for several months, and she was instead provided drinking water through a hose. The veterinary team suspected she did not visit the fountain area due to discomfort or pain in her limbs. Starting on January 8, after five weeks of CBD treatment, the patient visited the fountain area at least three recorded times to drink water or bathe. This could suggest a decrease in the discomfort or pain in her palms and soles.

There were several disruptions to this case study due to the COVID-19 pandemic in Mexico. A lockdown was implemented at the beginning of January, which affected the patient's husbandry and case follow-up. Unfortunately, this resulted in the loss of laboratory samples, having no weight records after 6 January 2021, and the interruption of the CBD treatment after 31 January 2021 due to financial limitations at the conservation park.

## Discussion

Several studies have focused on studying the phytocannabinoid cannabidiol (CBD) for being a non-psychoactive active principle and processing therapeutic effects as an inflammatory, anxiolytic, analgesic, appetite modulator and antibiotic, among others (di Marzo et al., 2001; Costa et al., 2007; Scuderi et al., 2009). Depending on its concentration, CBD may activate, antagonize, or inhibit cannabinoid receptors (CB1 and CB2), as well as ionotropic (TRP) and nuclear (PPAR) receptors. It is through these mechanisms that it provides analgesic, antioxidant, and anti-inflammatory effects (Atalay et al., 2020). If the patient is suffering from any illnesses causing imbalance in the activation or innovation of these receptors, the CBD will regulate their activity and help the organism back to a state of homeostasis. In the case of the elephant patient, there were incidental findings such as increased mobility, greater food intake and decreased food selectivity.

According to Buragohain et al, there is a greater prevalence of infected wounds in elephants under human care (46.15%), in ages 31 to 40 (42.85%), and in females (50%) (Buragohain et al., 2019). This correlates to the patient's characteristics except her age, since the Buragohain study had no individuals older than 50. However, it is possible to consider the data could be similar in older patients such as the elephant presented here.

A study performed by Wassmann et al presented a new antibacterial combination for the treatment of gram-positive (G+) bacterial infections using CBD and Bacitracin (BAC). Their results showed inhibition of bacteria such as *S. aureus* in the sample combining CBD and BAC, compared to the administration of the individual compounds (Wassmann et al., 2020). These results could explain the rapid improvement in the patient's abscesses once the CBD was added when prior treatments with a daily antiseptic regime had not provided consistently favorable results by themselves. Once the CBD was included, positive results were obtained in a short period of time (under two months). Further research is needed to demonstrate whether there are any antibacterial and anti-inflammatory effects given by the CBD in abscesses found in elephants.

Jayakumar mentions that feeding regimes rarely follow the nutritional requirements of elephants when they are found under human care. They are usually given a single fodder or forage for the entire year with no variations, with insufficient quantities and/or quality (Jayakumar et al., 2017). In the case presented here, the specific cause for the patient's decreased food intake is unknown, but it could be related to the abscesses, to the decreased locomotion, to a deficient diet (given she was highly selective), individual idiosyncrasies, or a mix of all of these variables. On the other hand, the ECS plays a vital role in the cerebral centers in charge of modulation of vital behaviors such as hunger, changes in glucose and lipid levels, and thus, weight changes in the animal. A characteristic of the CB1 receptor in GABA cells is appetite induction (Terral et al., 2020). Adding CBD to treat the abscesses also managed to modulate feeding behaviors in the patient,

decreasing selectivity, stimulated and increased food intake, going from a 60 or 70% up to a 90% intake and positively influencing the animals weight gain.

## Conclusions

Palmar and plantar abscesses are among the most common ailments found in the group of elephants in this conservation park. It is known that both treatment and resolution are usually complicated and delayed, so early detection and diagnosis, together with the conventional antiseptic treatments provided by the veterinary personnel and a systemic administration of CBD may result in a quicker recovery time for the patient than only cleaning the lesions with antiseptics.

In this particular elephant's case, the inclusion of CBD in her treatment was found to not only help in the improvement and healing of her abscesses, but also nearly eliminated food selectivity, modulated her food intake positively, and improved her locomotion. More research in elephants is needed in order to determine and standardize adequate dose ranges and applications for this species, as well as the pharmacokinetics and pharmacodynamics of cannabinoids by genus or species.

**Conflict of Interest Declarations:** Ortiz and Castillo are remunerated employees at ICAN, an enterprise that owns the compounding pharmacies that formulate Botican® magistral medications; they both declare not having received any payment or compensation for their participation in this research. Hernandez and Flores declare no conflict of interest.

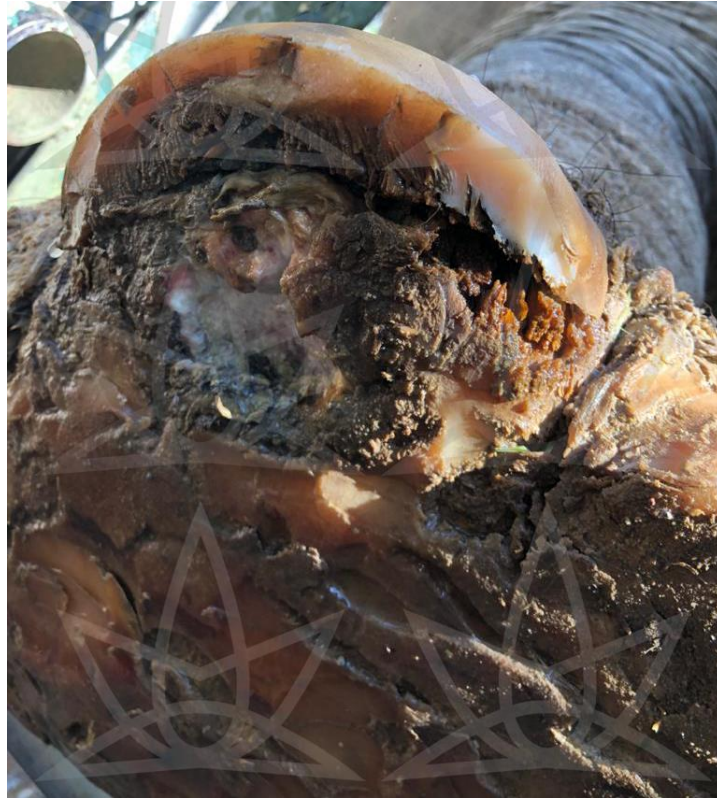**Financing:** This research did not receive any internal or external financing of any kind.

**Ethical Declarations:** This research includes one (1) animal subject. The Veterinarian Responsible for the Asian Elephants Area, the Head Veterinarian of the Elephant Area, and the Conservation Park Director were all aware of and approved the research on the animal subject after reviewing the research protocol internally.

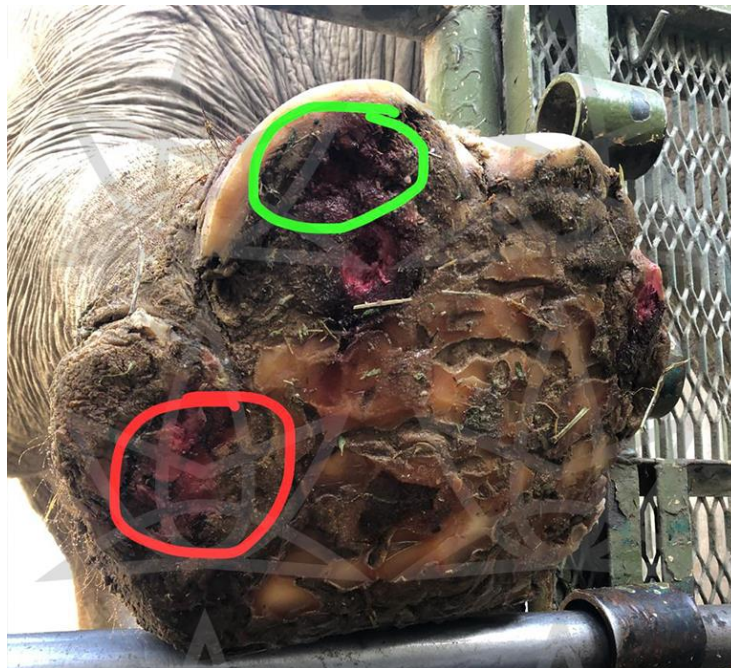
**Informed consent:** Informed consent (either verbal or written) was obtained from the Head Veterinarian of the Elephant Area of the Conservation Park. No animals or humans are identifiable within this publication, and therefore additional informed consent for publication was not required.



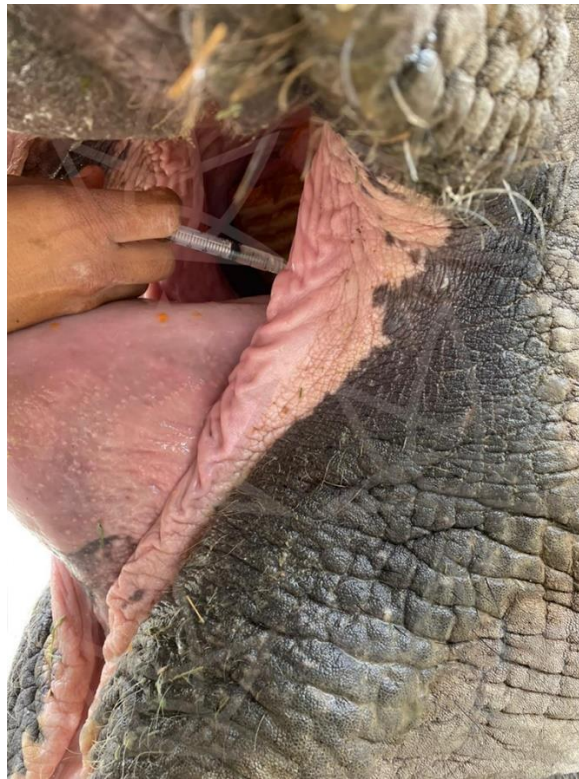## IMAGES



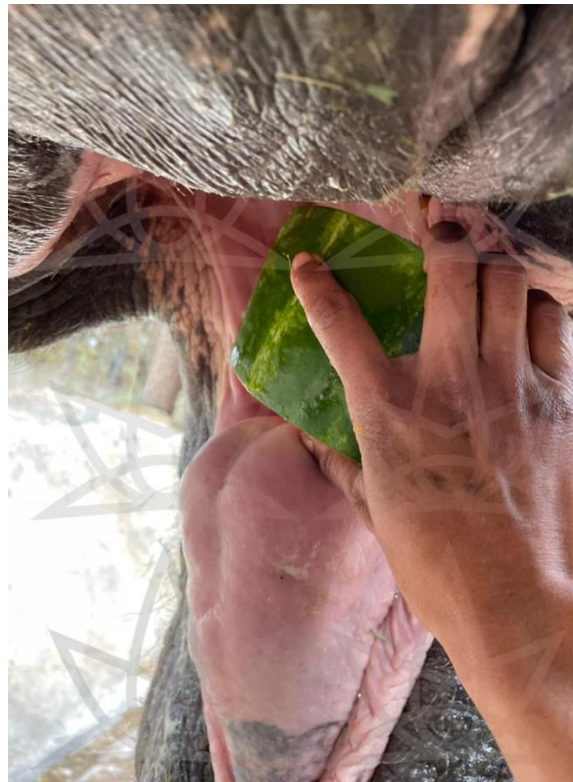**Image 1.** Fourth nail/h hoof of the right forelimb (RFL), August 9, 2020.



**Image 2.** Fourth and fifth nails/hooves RFL, October 2020. Abscess in nail 5 (red circle), abscess in nail 4 (green circle), abscess in nail 2 (not marked). The bright pink coloration of the tissues is due to benzalkonium chloride application.



**Image 3.** The patient has a prior training in protected handling; she opens her mouth and allows depositing the medication directly into the oral cavity.



**Image 4.** After depositing the medication behind the tongue, the patient is given a piece of fruit so that she swallows the medication and fruit together.





**Image 5.** Nail 4 RFL, December 6, 2020, after nine days on CBD treatment.



**Image 6.** Nail 4 RFL, December 10, 2020, after two weeks on CBD treatment.  
The white foam is residual antiseptic.





**Image 7.** Nails 4 and 5 RFL, December 26, 2020. The image shows the extent of the lesions before treatment with CBD (red circles) and after four weeks of treatment with CBD (green circles).



**Image 8.** Nails 4 and 5 RFL, January 16, 2021, after six weeks of CBD treatment. The image shows the size of the opening of the nail 5 abscess, which is nearly imperceptible (green circle), and the manual filing down of the tissue in nail 4 to allow the wound to close from the inside (green arrow).

## References

- Andre, C. M., Hausman, J. F., & Guerriero, G. (2016). Cannabis sativa: The plant of the thousand and one molecules. *Frontiers in Plant Science*, 7(FEB2016), 1–17. <https://doi.org/10.3389/fpls.2016.00019>
- Atalay, S., Jarocka-karpowicz, I., & Skrzydlewska, E. (2020). Antioxidative and anti-inflammatory properties of cannabidiol. *Antioxidants*, 9(1), 1–20. <https://doi.org/10.3390/antiox9010021>
- Buragohain, A., Mahato, G., Das, B. C., Phukan, A., & Sarma, K. K. (2019). Prevalence of wound infection in wild and captive elephants ( *Elephas maximus* ) of Assam. 7(6), 171–174.
- Costa, B., Trovato, A. E., Comelli, F., Giagnoni, G., & Colleoni, M. (2007). The non-psychoactive cannabis constituent cannabidiol is an orally effective therapeutic agent in rat chronic inflammatory and neuropathic pain. *European Journal of Pharmacology*, 556(1–3), 75–83. <https://doi.org/10.1016/j.ejphar.2006.11.006>
- de Petrocellis, L., Melck, D., Bisogno, T., Milone, A., & di Marzo, V. (1999). Finding of the endocannabinoid signalling system in Hydra, a very primitive organism: Possible role in the feeding response. *Neuroscience*, 92(1), 377–387. [https://doi.org/10.1016/S0306-4522\(98\)00749-0](https://doi.org/10.1016/S0306-4522(98)00749-0)
- di Marzo, V., Goparaju, S. K., Wang, L., Liu, J., Bátkai, S., Járαι, Z., Fezza, F., Miura, G. I., Palmiter, R. D., Sugiura, T., & Kunos, G. (2001). Leptin-regulated endocannabinoids are involved in maintaining food intake. *Nature*, 410(6830), 822–825. <https://doi.org/10.1038/35071088>
- Ellis, K. L., & Contino, E. K. (2019). Treatment using cannabidiol in a horse with mechanical allodynia. *Equine Veterinary Education*. <https://doi.org/10.1111/eve.13168>
- Fowler, M. E., & Mikota, S. K. (2006). *BIOLOGY, MEDICINE, AND SURGERY OF ELEPHANTS* (First edit). Blackwell Publishing Ltd. <http://library1.nida.ac.th/termpaper6/sd/2554/19755.pdf>
- Hazzah, T., Andre, C., Richter, G., & McGrath, S. (2020). Cannabis in Veterinary Medicine : A Critical Review. *AHVMA Journal*, 61, 17–41.
- Jayakumar, S., Sathiskumar, S., Baskaran, N., Arumugam, R., & Vanitha, V. (2017). Ethno-veterinary practices in Southern India for captive Asian elephant ailments. *Journal of Ethnopharmacology*, 200, 182–204. <https://doi.org/10.1016/j.jep.2017.02.039>
- Kumar, N., Natarasan, K., Sugumar, K., Kumar, V. S., Velmurugan, R., & Shanmugasundaram, P. (2019). Therapeutic management of wounds in Asian elephants. *Drug Invention Today*, 11 (Special Issue 2), 237–240.
- Luedke, C. (2020, 9-13 de noviembre). *Cáñamo para caballos: revisión de casos clínicos y protocolos de dosificación* [Presentación de congreso]. VETCANN ONLINE 2020.
- Miller, D., Jackson, B., Riddle, H. S., Stremme, C., Schmitt, D., & Miller, T. (2015). Elephant (*Elephas maximus*) health and management in Asia: Variations in veterinary perspectives. *Veterinary Medicine International*, 2015. <https://doi.org/10.1155/2015/614690>
- Nevett, J. (2020, Agosto 25). *Elephant at Warsaw zoo to test cannabis-extract oil*. BBC NEWS. [https://www.bbc.com/news/world-europe-53907689?\\_ga=2.71692627.1952482172.1598556916-1174096916.1598556916](https://www.bbc.com/news/world-europe-53907689?_ga=2.71692627.1952482172.1598556916-1174096916.1598556916)
- Patil, A. S., Mahajan, U. B., Agrawal, Y. O., Patil, K. R., Patil, C. R., Ojha, S., Sharma, C., & Goyal, S. N. (2020). Plant-derived natural therapeutics targeting cannabinoid receptors in metabolic syndrome and its complications: A review. *Biomedicine and Pharmacotherapy*, 132, 110889. <https://doi.org/10.1016/j.biopha.2020.110889>
- Russo, E. B., & Marcu, J. (2017). Cannabis Pharmacology: The Usual Suspects and a Few Promising Leads. In *Advances in Pharmacology* (1st ed., Vol. 80). Elsevier Inc. <https://doi.org/10.1016/bs.apha.2017.03.004>
- Scuderi, C., Filippis, D. D., Iuvone, T., Blasio, A., Steardo, A., & Esposito, G. (2009). Cannabidiol in medicine: a review of its therapeutic potential in CNS disorders. *Phytotherapy Research*, 23(4), 597–602. <https://doi.org/10.1002/ptr.2625>
- Silver, R. J. (2019). The Endocannabinoid System of Animals. *Animals*, 9(9), 686. <https://doi.org/10.3390/ani9090686>
- Terral, G., Marsicano, G., Grandes, P., & Soria-Gómez, E. (2020). Cannabinoid control of olfactory processes: The where matters. In *Genes* (Vol. 11, Issue 4). MDPI AG. <https://doi.org/10.3390/genes11040431>
- Wassmann, C. S., Højrup, P., & Klitgaard, J. K. (2020). Cannabidiol is an effective helper compound in combination with bacitracin to kill Gram-positive bacteria. *Scientific Reports*, 10(1), 1–12. <https://doi.org/10.1038/s41598-020-60952-0>